



# Dermatophytosis

From Wikipedia, the free encyclopedia

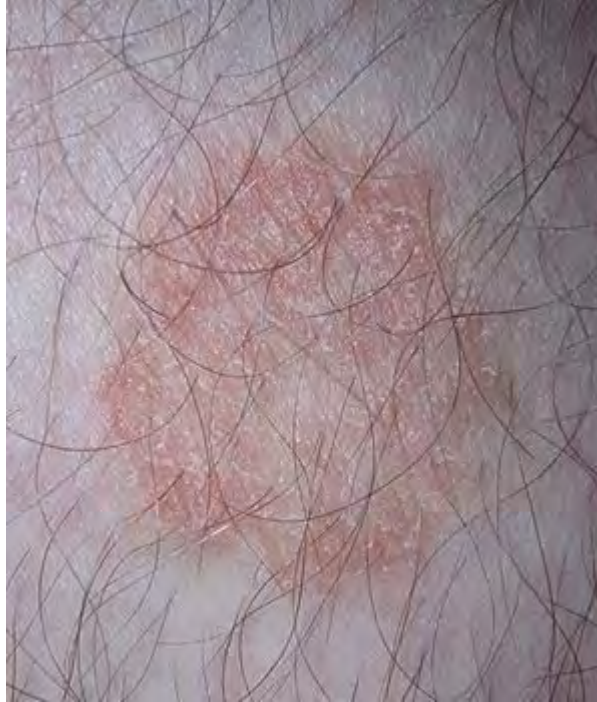**Dermatophytosis**, also known as **ringworm**, is a fungal infection of the skin.<sup>[1]</sup> Typically it results in a red, itchy, scaly, circular rash. Hair loss may occur in the area affected. Symptoms begin four to fourteen days after exposure.<sup>[2]</sup> Multiple areas can be affected at a given time.<sup>[3]</sup>

About 40 types of fungi can cause ringworm. They are typically of the *Trichophyton*, *Microsporum*, or *Epidermophyton* type.<sup>[1]</sup> Risk factors include using public showers, contact sports such as wrestling, excessive sweating, contact with animals, obesity, and poor immune function.<sup>[4][3]</sup> Ringworm can spread from other animals or between people.<sup>[4]</sup> Diagnosis is often based on the appearance and symptoms. It may be confirmed by either culturing or looking at a skin scraping under a microscope.<sup>[5]</sup>

Prevention is by keeping the skin dry, not walking barefoot in public, and not sharing personal items.<sup>[4]</sup> Treatment is typically with antifungal creams such as

## Dermatophytosis

**Synonyms** ringworm, tinea



Ringworm on a human leg.

### Classification and external resources

<b>Specialty</b>	Dermatology
<b>ICD-10</b>	B35.0 ( <a href="http://apps.who.int/classifications/icd10/browse/2016/en#/B35.0">http://apps.who.int/classifications/icd10/browse/2016/en#/B35.0</a> ) -B36 ( <a href="http://apps.who.int/classifications/icd10/browse/2016/en#/B36">http://apps.who.int/classifications/icd10/browse/2016/en#/B36</a> )
<b>ICD-9-CM</b>	110.9 ( <a href="http://www.icd9data.com/getICD9Code.aspx?icd9=110.9">http://www.icd9data.com/getICD9Code.aspx?icd9=110.9</a> )
<b>DiseasesDB</b>	17492 ( <a href="http://www.diseasesdatabase.com/ddb17492.htm">http://www.diseasesdatabase.com/ddb17492.htm</a> )
<b>MedlinePlus</b>	001439 ( <a href="https://medlineplus.gov/ency/article/001439.htm">https://medlineplus.gov/ency/article/001439.htm</a> )
<b>eMedicine</b>	emerg/592 ( <a href="http://www.emedicine.com/emerg/topic592.htm">http://www.emedicine.com/emerg/topic592.htm</a> )
<b>Patient UK</b>	Dermatophytosis ( <a href="http://patient.info/doctor/dermatophytosis-tinea-infections">http://patient.info/doctor/dermatophytosis-tinea-infections</a> )
<b>MeSH</b>	D003881 ( <a href="https://www.nlm.nih.gov/cgi/mesh/2016/MB_cgi?field=uid&amp;term=D003881">https://www.nlm.nih.gov/cgi/mesh/2016/MB_cgi?field=uid&amp;term=D003881</a> )

clotrimazole or miconazole. If the scalp is involved antifungals by mouth such as fluconazole may be needed.<sup>[6]</sup>

Up to 20% of the population may be infected by ringworm at any given time.<sup>[7]</sup> Infections of the groin are more common in males, while infections of the scalp and body occur equally in both sexes.<sup>[3]</sup> Infections of the scalp are most common in children while infections of the groin are most common in the elderly.<sup>[3]</sup> Description of ringworm date back to ancient history.<sup>[8]</sup>

## Contents

- 1 Signs and symptoms
- 2 Causes
- 3 Classification
- 4 Prevention
  - 4.1 Vaccination
- 5 Treatment
- 6 History
- 7 Society and culture
- 8 Other animals
  - 8.1 Diagnosis
  - 8.2 Treatment
- 9 References
- 10 External links

## Signs and symptoms

Infections on the body may give rise to typical enlarging raised red rings of ringworm. Infection on the skin of the feet may cause athlete's foot and in the groin, jock itch. Involvement of the nails is termed onychomycosis, and they may thicken, discolour, and finally crumble and fall off. They are common in most adult people, with up to 20% of the population having one of these infections at any given moment.

Animals such as dogs and cats can also be affected by ringworm, and the disease can be transmitted between animals and humans, making it a zoonotic disease.

Specific signs can be:

- red, scaly, itchy or raised patches
- patches may be redder on outside edges or resemble a ring
- patches that begin to ooze or develop blister
- bald patches may develop, when the scalp is affected
- nails may thicken, discolour or begin to crack<sup>[9]</sup>

## Causes

Fungi thrive in moist, warm areas, such as locker rooms, tanning beds, swimming pools, and skin folds; accordingly, those that cause dermatophytosis may be spread by using exercise machines that have not been disinfected after use, or by sharing towels, clothing, or footwear, such as rental bowling shoes, ski boots, ice skates or roller skates.

## Classification

A number of different species of fungi are involved in dermatophytosis. Dermatophytes of the genera *Trichophyton* and *Microsporum* are the most common causative agents. These fungi attack various parts of the body and lead to the conditions listed below. The Latin names are for the conditions (disease patterns), not the agents that cause them. The disease patterns below identify the type of fungus that causes them only in the cases listed:

- Dermatophytosis
  - Tinea pedis (athlete's foot) – fungal infection of the feet
  - Tinea unguium – fungal infection of the fingernails and toenails, and the nail bed
  - Tinea corporis – fungal infection of the arms, legs, and trunk
  - Tinea cruris (jock itch) – fungal infection of the groin area
  - Tinea manuum – fungal infection of the hands and palm area
  - Tinea capitis – fungal infection of the scalp and hair
  - Tinea barbae – fungal infestation of facial hair
  - Tinea faciei (face fungus) – fungal infection of the face
- Other superficial mycoses (not classic ringworm, since not caused by dermatophytes)
  - Tinea versicolor – caused by *Malassezia furfur*
  - Tinea nigra – caused by *Hortaea werneckii*

## Prevention

Advice often given includes:

- Avoid sharing clothing, sports equipment, towels, or sheets.
- Wash clothes in hot water with fungicidal soap after suspected exposure to ringworm.
- Avoid walking barefoot; instead wear appropriate protective shoes in locker rooms and sandals at the beach.<sup>[10][11][12]</sup>
- Avoid touching pets with bald spots, as they are often carriers of the fungus.

## Vaccination

As of 2016, no approved human vaccine exist against *Dermatophytosis*. For horses, dogs and cats there is available an approved inactivated vaccine called *Insol Dermatophyton* (Boehringer Ingelheim) which provides time-limited protection against several trichophyton and microsporum fungal strains.<sup>[13]</sup>

## Treatment

Antifungal treatments include topical agents such as miconazole, terbinafine, clotrimazole, ketoconazole, or tolnaftate applied twice daily until symptoms resolve — usually within one or two weeks.<sup>[14]</sup> Topical treatments should then be continued for a further 7 days after resolution of visible symptoms to prevent recurrence.<sup>[14][15]</sup> The total duration of treatment is therefore generally two weeks,<sup>[16][17]</sup> but may be as long as three.<sup>[18]</sup>

In more severe cases or scalp ringworm, systemic treatment with oral medications may be given.<sup>[19]</sup>

To prevent spreading the infection, lesions should not be touched, and good hygiene maintained with washing of hands and the body.<sup>[20]</sup>

Misdiagnosis and treatment of ringworm with a topical steroid, a standard treatment of the superficially similar pityriasis rosea, can result in tinea incognito, a condition where ringworm fungus grows without typical features, such as a distinctive raised border.

## History

Dermatophytosis has been prevalent since before 1906, at which time ringworm was treated with compounds of mercury or sometimes sulfur or iodine. Hairy areas of skin were considered too difficult to treat, so the scalp was treated with X-rays and followed up with antiparasitic medication.<sup>[21]</sup> Another treatment from around the same time was application of Araroba powder.<sup>[22]</sup>

## Society and culture

The most common term for the infection, "ringworm", is a misnomer, since the condition is caused by fungi of several different species and not by parasitic worms.

## Other animals

Ringworm caused by *Trichophyton verrucosum* is a frequent clinical condition in cattle. Young animals are more frequently affected. The lesions are located on the head, neck, tail, and perineum.<sup>[23]</sup> The typical lesion is a round, whitish crust. Multiple lesions may coalesce in "map-like" appearance.



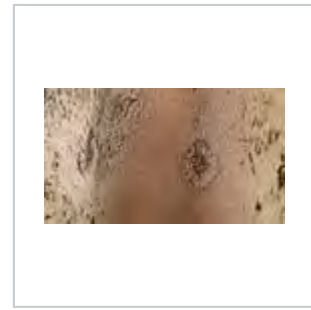
Multiple lesions, head




Around the eyes and on ears




On cheeks: crusted lesion (right)



Old lesions, with regrowing hair



On neck and withers



On perineum

Clinical dermatophytosis is also diagnosed in sheep, dogs, cats, and horses. Causative agents, besides *Trichophyton verrucosum*, are *T. mentagrophytes*, *T. equinum*, *Microsporum gypseum*, *M. canis*, and *M. nanum*.<sup>[24]</sup>

Dermatophytosis may also be present in the holotype of the Cretaceous eutriconodont mammal *Spinolestes*, suggesting a Mesozoic origin for this disease.

## Diagnosis

Ringworm in pets may often be asymptomatic, resulting in a carrier condition which infects other pets. In some cases, the disease only appears when the animal develops an immunodeficiency condition. Circular bare patches on the skin suggest the diagnosis, but no lesion is truly specific to the fungus. Similar patches may result from allergies, sarcoptic mange, and other conditions. Three species of fungi cause 95% of dermatophytosis in pets: these are *Microsporum canis*, *Microsporum gypseum*, and *Trichophyton mentagrophytes*.

Veterinarians have several tests to identify ringworm infection and identify the fungal species that cause it:

**Woods test:** This is an ultraviolet light with a magnifying lens. Only 50% of *M. canis* will show up as an apple-green fluorescence on hair shafts, under the UV light. The other fungi do not show. The fluorescent material is not the fungus itself (which does not fluoresce), but rather an excretory product of the fungus which sticks to hairs. Infected skin does not fluoresce.

**Microscopic test:** The veterinarian takes hairs from around the infected area and places them in a staining solution to view under the microscope. Fungal spores may be viewed directly on hair shafts. This technique identifies a fungal infection in about 40%–70% of the infections, but cannot identify the species of dermatophyte.

**Culture test:** This is the most effective, but also the most time-consuming, way to determine if ringworm is on a pet. In this test, the veterinarian collects hairs from the pet, or else collects fungal spores from the pet's hair with a toothbrush, or other instrument, and inoculates fungal media for culture. These cultures can be brushed with transparent tape and then read by the veterinarian using a microscope, or can be sent to a pathological lab. The three common types of fungi which commonly cause pet ringworm can be identified by their characteristic spores. These are different-appearing macroconidia in the two common species of *Microspora*, and typical microconidia in *Trichophyton* infections.<sup>[24]</sup>

Identifying the species of fungi involved in pet infections can be helpful in controlling the source of infection. *M. canis*, despite its name, occurs more commonly in domestic cats, and 98% of cat infections are with this organism. It can also infect dogs and humans, however. *T. mentagrophytes* has a major reservoir in rodents, but can also infect pet rabbits, dogs, and horses. *M. gypseum* is a soil organism and is often contracted from gardens and other such places. Besides humans, it may infect rodents, dogs, cats, horses, cattle, and swine.<sup>[25]</sup>

## Treatment

### Pet animals

Treatment requires both systemic oral treatment with most of the same drugs used in humans—terbinafine, fluconazole, or itraconazole—as well as a topical "dip" therapy.<sup>[26]</sup>

Because of the usually longer hair shafts in pets compared to those of humans, the area of infection and possibly all of the longer hair of the pet must be clipped to decrease the load of fungal spores clinging to the pet's hair shafts. However, close shaving is usually not done because nicking the skin facilitates further skin infection.

Twice-weekly bathing of the pet with diluted lime sulfur dip solution is effective in eradicating fungal spores. This must continue for 3 to 8 weeks.<sup>[27]</sup>

Washing of household hard surfaces with 1:10 household sodium hypochlorite bleach solution is effective in killing spores, but it is too irritating to be used directly on hair and skin.

Pet hair must be rigorously removed from all household surfaces, and then the vacuum cleaner bag, and perhaps even the vacuum cleaner itself, discarded when this has been done repeatedly. Removal of all hair is important, since spores may survive 12 months or even as long as two years on hair clinging to surfaces.<sup>[28]</sup>

### Cows

In bovines, an infestation is difficult to cure, as systemic treatment is uneconomical. Local treatment with iodine compounds is time-consuming, as it needs scraping of crusty lesions. Moreover, it must be carefully conducted using gloves, lest the worker become infested.

## References

1. "Definition of Ringworm". *CDC*. December 6, 2015. Retrieved 5 September 2016.
2. "Symptoms of Ringworm Infections". *CDC*. December 6, 2015. Retrieved 5 September 2016.
3. Domino, Frank J.; Baldor, Robert A.; Golding, Jeremy (2013). *The 5-Minute Clinical Consult 2014*. Lippincott Williams & Wilkins. p. 1226. ISBN 9781451188509.
4. "Ringworm Risk & Prevention". *CDC*. December 6, 2015. Retrieved 5 September 2016.
5. "Diagnosis of Ringworm". *CDC*. December 6, 2015. Retrieved 5 September 2016.
6. "Treatment for Ringworm". *CDC*. December 6, 2015. Retrieved 5 September 2016.
7. Mahmoud A. Ghannoum; John R. Perfect (24 November 2009). *Antifungal Therapy*. CRC Press. p. 258. ISBN 978-0-8493-8786-9.
8. Bologna, Jean L.; Jorizzo, Joseph L.; Schaffer, Julie V. (2012). *Dermatology* (3 ed.). Elsevier Health Sciences. p. 1255. ISBN 0702051829.
9. "recognizing Ringworm". *Healthline*.
10. Klemm, Lori (2 April 2008). "Keeping footloose on trips". *The Herald News*.
11. Fort Dodge Animal Health: ([https://web.archive.org/web/20080604090756/http://www.wyeth.com/animalhealth?rid=/wyeth\\_html/home/user\\_group\\_landing/for\\_ahp/fortdodge\\_overview.html](https://web.archive.org/web/20080604090756/http://www.wyeth.com/animalhealth?rid=/wyeth_html/home/user_group_landing/for_ahp/fortdodge_overview.html)) Milestones from Wyeth.com. Retrieved April 28, 2008.
12. Ringworm In Your Dog Cat Or Other Pet: (<http://www.2ndchance.info/ringworm.htm>) Prevention by Ron Hines DVM PhD 5/4/06. Retrieved April 28, 2008.
13. "Insol Dermatophyton 5x2 ml". GROVET - The veterinary warehouse. Retrieved 2016-02-01.
14. Kyle AA, Dahl MV (2004). "Topical therapy for fungal infections". *Am J Clin Dermatol*. **5** (6): 443–51. PMID 15663341.
15. McClellan KJ, Wiseman LR, Markham A (July 1999). "Terbinafine. An update of its use in superficial mycoses". *Drugs*. **58** (1): 179–202. doi:10.2165/00003495-199958010-00018. PMID 10439936.
16. *Tinea~treatment* (<http://emedicine.medscape.com/article/787217-treatment>) at eMedicine
17. *Tinea Corporis~treatment* (<http://emedicine.medscape.com/article/1091473-treatment>) at eMedicine
18. "Antifungal agents for common paediatric infections". *Can J Infect Dis Med Microbiol*. **19** (1): 15–8. January 2008. PMC 2610275  PMID 19145261.
19. Gupta AK, Cooper EA (2008). "Update in antifungal therapy of dermatophytosis". *Mycopathologia*. **166** (5–6): 353–67. doi:10.1007/s11046-008-9109-0. PMID 18478357.
20. *Ringworm on Body Treatment* ([http://www.emedicinehealth.com/ringworm\\_on\\_body/article\\_em.htm](http://www.emedicinehealth.com/ringworm_on_body/article_em.htm)) at eMedicineHealth
21. Sequeira, J.H. (1906). "The Varieties of Ringworm and Their Treatment" (PDF). *British Medical Journal*. **2** (2378): 193. doi:10.1136/bmj.2.2378.193.
22. Mrs. M. Grieve. *A Modern Herbal*.
23. Scott, David W. (2007). *Colour Atlas of Animal Dermatology*. Blackwell. ISBN 978-0-8138-0516-0.
24. "Ringworm in Dogs Diagnosis". Dogclassonline.com. Retrieved 2011-01-10.
25. "General ringworm information". Ringworm.com.au. Retrieved 2011-01-10.
26. [1] (<http://www.newmanveterinary.com/Facts%20About%20Ringworm.html>) Detailed veterinary discussion of animal treatment
27. "Veterinary treatment site page". Marvistavet.com. Retrieved 2011-01-10.
28. "Persistence of spores". Ringworm.com.au. Retrieved 2011-01-10.

## External links

- Tinea photo library at Dermnet (<http://www.dermnet.com/moduleSearch.cfm?searchTerm=tinea>)

Retrieved from "<https://en.wikipedia.org/w/index.php?title=Dermatophytosis&oldid=752403325>"

Categories: [Animal fungal diseases](#) | [Mycosis-related cutaneous conditions](#)

---

- This page was last modified on 1 December 2016, at 01:48.
- Text is available under the Creative Commons Attribution-ShareAlike License; additional terms may apply. By using this site, you agree to the Terms of Use and Privacy Policy. Wikipedia® is a registered trademark of the Wikimedia Foundation, Inc., a non-profit organization.