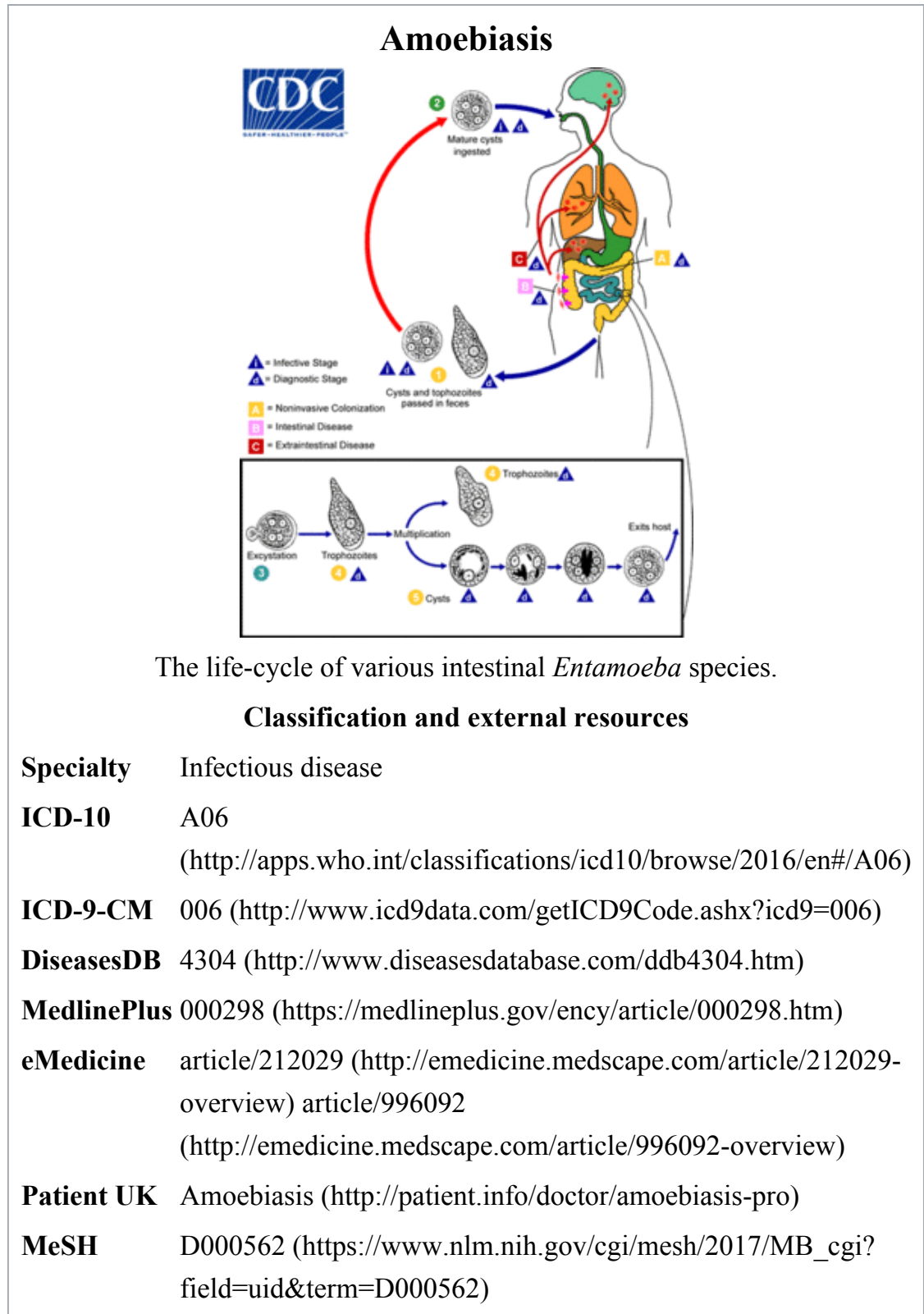


Amoebiasis

From Wikipedia, the free encyclopedia



Amoebiasis, also known as **amebiasis** or **entamoebiasis**,^{[1][2]} is an infection caused by any of the amoebas of the *Entamoeba* group. Symptoms are most common upon infection by *Entamoeba histolytica*. Amoebiasis can present with no, mild, or severe symptoms. Symptoms may include abdominal pain, mild diarrhoea, bloody diarrhea or severe colitis with tissue death and perforation. This last complication may cause peritonitis. People affected may develop anemia due to loss of blood.^[3]

Invasion of the intestinal lining causes amoebic bloody diarrhea or amoebic colitis. If the parasite reaches the bloodstream it can spread through the body, most frequently ending up in the liver where it causes amoebic liver abscesses. Liver abscesses can occur without previous diarrhea. Cysts of *Entamoeba* can survive for up to a month in soil or for up to 45 minutes under fingernails. It is important to differentiate between amoebiasis and bacterial colitis. The preferred diagnostic method is through faecal examination under microscope, but requires a skilled microscopist and may not be reliable when excluding infection. This method however may not be able to separate between specific types. Increased white blood cell count is present in severe cases, but not in mild ones. The most accurate test is for antibodies in the blood, but it may remain positive following treatment.^[3]

Prevention of amoebiasis is by separating food and water from faeces and by proper sanitation measures. There is no vaccine. There are two treatment options depending on the location of the infection. Amoebiasis in tissues is treated with either metronidazole, tinidazole, nitazoxanide, dehydroemetine or chloroquine, while luminal infection is treated with diloxanide furoate or iodoquinoline. For treatment to be effective against all stages of the amoeba may require a combination of medications. Infections without symptoms do not require treatment but infected individuals can spread the parasite to others and treatment can be considered.

Treatment of other *Entamoeba* infections apart from *E. histolytica* is not needed.^[3]

Amoebiasis is present all over the world.^[4] About 480 million people are infected with what appears to be *E. histolytica* and these result in the death of between 40,000–110,000 people every year. Most infections are now ascribed to *E. dispar*. *E. dispar* is more common in certain areas and symptomatic cases may be fewer than previously reported. The first case of amoebiasis was documented in 1875 and in 1891 the disease was described in detail, resulting in the terms *amoebic dysentery* and *amoebic liver abscess*. Further evidence from the Philippines in 1913 found that upon ingesting cysts of *E. histolytica* volunteers developed the disease. It has been

known since 1897 that at least one non-disease-causing species of *Entamoeba* existed (*Entamoeba coli*), but it was first formally recognized by the WHO in 1997 that *E. histolytica* was two species, despite this having first been proposed in 1925. In addition to the now-recognized *E. dispar* evidence shows there are at least two other species of *Entamoeba* that look the same in humans - *E. moshkovskii* and *Entamoeba bangladeshi*. The reason these species haven't been differentiated until recently is because of the reliance on appearance.^[3]

Contents

- 1 Signs and symptoms
- 2 Cause
 - 2.1 Transmission
- 3 Diagnosis
- 4 Prevention
- 5 Treatment
- 6 Prognosis
- 7 Epidemiology
- 8 History
- 9 References
- 10 External links

Signs and symptoms

Most infected people, about 90%,^[5] are asymptomatic, but this disease has the potential to make the sufferer dangerously ill. It is estimated that about 40,000 to 100,000 people worldwide die annually due to amoebiasis.^[6]

Infections can sometimes last for years. Symptoms take from a few days to a few weeks to develop and manifest themselves, but usually it is about two to four weeks. Symptoms can range from mild diarrhea to severe dysentery with blood and mucus. The blood comes from lesions formed by the amoebae invading the lining of the large intestine. In about 10% of invasive cases the amoebae enter the bloodstream

and may travel to other organs in the body. Most commonly this means the liver,^[7] as this is where blood from the intestine reaches first, but they can end up almost anywhere in the body.

Onset time is highly variable and the average asymptomatic infection persists for over a year. It is theorized that the absence of symptoms or their intensity may vary with such factors as strain of amoeba, immune response of the host, and perhaps associated bacteria and viruses.

In asymptomatic infections the amoeba lives by eating and digesting bacteria and food particles in the gut, a part of the gastrointestinal tract. It does not usually come in contact with the intestine itself due to the protective layer of mucus that lines the gut. Disease occurs when amoeba comes in contact with the cells lining the intestine. It then secretes the same substances it uses to digest bacteria, which include enzymes that destroy cell membranes and proteins. This process can lead to penetration and digestion of human tissues, resulting first in flask-shaped ulcers in the intestine. *Entamoeba histolytica* ingests the destroyed cells by phagocytosis and is often seen with red blood cells (a process known as erythrophagocytosis) inside when viewed in stool samples. Especially in Latin America, a granulomatous mass (known as an amoeboma) may form in the wall of the ascending colon or rectum due to long-lasting immunological cellular response, and is sometimes confused with cancer.^[8]

"Theoretically, the ingestion of one viable cyst can cause an infection."^[9]

Cause

Amoebiasis is an infection caused by the amoeba *Entamoeba histolytica*. Likewise amoebiasis is sometimes incorrectly used to refer to infection with other amoebae, but strictly speaking it should be reserved for *Entamoeba histolytica* infection. Other amoebae infecting humans include:^[10]

- Parasites
 - *Dientamoeba fragilis*, which causes Dientamoebiasis
 - *Entamoeba dispar*
 - *Entamoeba hartmanni*
 - *Entamoeba coli*
 - *Entamoeba moshkovskii*

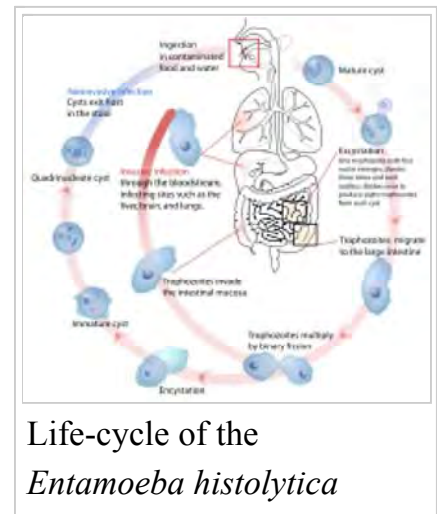
- *Endolimax nana* and
- *Iodamoeba butschlii*.

Except for *Dientamoeba*, the parasites above are not thought to cause disease.

- Free living amoebas.^{[11][12]} These species are often described as "opportunistic free-living amoebas" as human infection is not an obligate part of their life cycle.
 - *Naegleria fowleri*, which causes Primary amoebic meningoencephalitis
 - *Acanthamoeba*, which causes Cutaneous amoebiasis^[13] and Acanthamoeba keratitis
 - *Balamuthia mandrillaris*,^[14] which causes Granulomatous amoebic encephalitis and Primary amoebic meningoencephalitis
 - *Sappinia diploidea*

Transmission

Amoebiasis is usually transmitted by the fecal-oral route, but it can also be transmitted indirectly through contact with dirty hands or objects as well as by anal-oral contact. Infection is spread through ingestion of the cyst form of the parasite, a semi—dormant and hardy structure found in feces. Any non-encysted amoebae, or *trophozoites*, die quickly after leaving the body but may also be present in stool: these are rarely the source of new infections. Since amoebiasis is transmitted through contaminated food and water, it is often endemic in regions of the world with limited modern sanitation systems, including México, Central America, western South America, South Asia, and western and southern Africa.^[15]



Life-cycle of the
Entamoeba histolytica

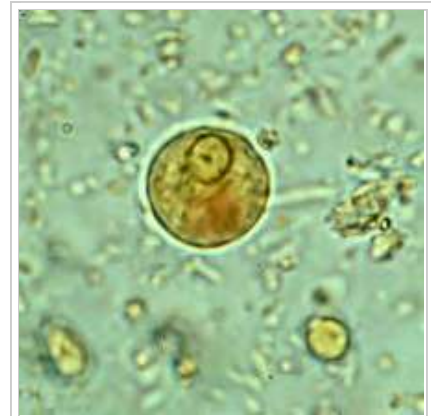Amoebic dysentery is often confused with "traveler's diarrhea" because of its prevalence in developing nations. In fact, most traveler's diarrhea is bacterial or viral in origin.

Diagnosis

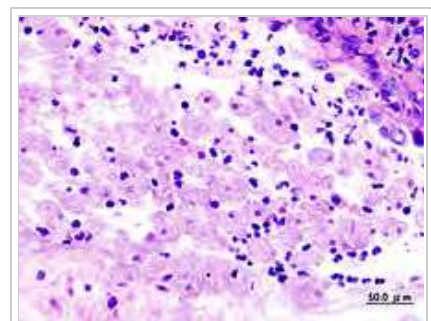
With colonoscopy it is possible to detect small ulcers of between 3–5mm, but diagnosis may be difficult as the mucous membrane between these areas can look either healthy or inflamed.^[3]

Asymptomatic human infections are usually diagnosed by finding cysts shed in the stool. Various flotation or sedimentation procedures have been developed to recover the cysts from fecal matter and stains help to visualize the isolated cysts for microscopic examination. Since cysts are not shed constantly, a minimum of three stools should be examined. In symptomatic infections, the motile form (the trophozoite) can often be seen in fresh feces. Serological tests exist and most individuals (whether with symptoms or not) will test positive for the presence of antibodies. The levels of antibody are much higher in individuals with liver abscesses. Serology only becomes positive about two weeks after infection. More recent developments include a kit that detects the presence of amoeba proteins in the feces and another that detects amoeba DNA in feces. These tests are not in widespread use due to their expense.

Microscopy is still by far the most widespread method of diagnosis around the world. However it is not as sensitive or accurate in diagnosis as the other tests available. It is important to distinguish the *E. histolytica* cyst from the cysts of nonpathogenic intestinal protozoa such as *Entamoeba coli* by its appearance. *E. histolytica* cysts have a maximum of four nuclei, while the commensal *Entamoeba coli* cyst has up to 8 nuclei. Additionally, in *E. histolytica*, the endosome is centrally located in the nucleus, while it is usually off-center in *Entamoeba coli*. Finally, chromatoidal bodies in *E. histolytica* cysts are rounded, while they are jagged in *Entamoeba coli*. However, other species, *Entamoeba dispar* and *E. moshkovskii*, are also commensals and cannot be



Immature *E. histolytica*/*E. dispar* cyst in a concentrated wet mount stained with iodine. This early cyst has only one nucleus and a glycogen mass is visible (brown stain). From CDC's Division of Parasitic Diseases



Amoebae in a colon biopsy from a case of amoebic dysentery.

distinguished from *E. histolytica* under the microscope. As *E. dispar* is much more common than *E. histolytica* in most parts of the world this means that there is a lot of incorrect diagnosis of *E. histolytica* infection taking place. The WHO recommends that infections diagnosed by microscopy alone should not be treated if they are asymptomatic and there is no other reason to suspect that the infection is actually *E. histolytica*. Detection of cysts or trophozoites stools under microscope may require examination of several samples over several days to determine if they are present, because cysts are shed intermittently and may not show up in every sample.

Typically, the organism can no longer be found in the feces once the disease goes extra-intestinal. Serological tests are useful in detecting infection by *E. histolytica* if the organism goes extra-intestinal and in excluding the organism from the diagnosis of other disorders. An Ova & Parasite (O&P) test or an *E. histolytica* fecal antigen assay is the proper assay for intestinal infections. Since antibodies may persist for years after clinical cure, a positive serological result may not necessarily indicate an active infection. A negative serological result however can be equally important in excluding suspected tissue invasion by *E. histolytica*.

Prevention

To help prevent the spread of amoebiasis around the home :

- Wash hands thoroughly with soap and hot running water for at least 10 seconds after using the toilet or changing a baby's diaper, and before handling food.
- Clean bathrooms and toilets often; pay particular attention to toilet seats and taps.
- Avoid sharing towels or face washers.

To help prevent infection:

- Avoid raw vegetables when in endemic areas, as they may have been fertilized using human feces.
- Boil water or treat with iodine tablets.
- Avoid eating street foods especially in public places where others are sharing sauces in one container



Amoebic ulcer in the intestines

Good sanitary practice, as well as responsible sewage disposal or treatment, are necessary for the prevention of *E. histolytica* infection on an endemic level.

E. histolytica cysts are usually resistant to chlorination, therefore sedimentation and filtration of water supplies are necessary to reduce the incidence of infection.^[16]

E. histolytica cysts may be recovered from contaminated food by methods similar to those used for recovering *Giardia lamblia* cysts from feces. Filtration is probably the most practical method for recovery from drinking water and liquid foods. *E. histolytica* cysts must be distinguished from cysts of other parasitic (but nonpathogenic) protozoa and from cysts of free-living protozoa as discussed above. Recovery procedures are not very accurate; cysts are easily lost or damaged beyond recognition, which leads to many falsely negative results in recovery tests.^[17]

Treatment

E. histolytica infections occur in both the intestine and (in people with symptoms) in tissue of the intestine and/or liver.^[15] As a result, two different classes of drugs are needed to treat the infection, one for each location. Such anti-amoebic drugs are known as amoebicides.

Prognosis

In the majority of cases, amoebas remain in the gastrointestinal tract of the hosts. Severe ulceration of the gastrointestinal mucosal surfaces occurs in less than 16% of cases. In fewer cases, the parasite invades the soft tissues, most commonly the liver.

^[7] Only rarely are masses formed (amoebomas) that lead to intestinal obstruction. (Mistaken for Ca caecum and appendicular mass) Other local complications include bloody diarrhea, pericolic and pericaecal abscess.

Complications of hepatic amoebiasis includes subdiaphragmatic abscess, perforation of diaphragm to pericardium and pleural cavity, perforation to abdominal cavital (*amoebic peritonitis*) and perforation of skin (*amoebiasis cutis*).

Pulmonary amoebiasis can occur from hepatic lesion by haematogenous spread and also by perforation of pleural cavity and lung. It can cause lung abscess, pulmono pleural fistula, empyema lung and broncho pleural fistula. It can also reach the brain through blood vessels and cause amoebic brain abscess and amoebic

meningoencephalitis. Cutaneous amoebiasis can also occur in skin around sites of colostomy wound, perianal region, region overlying visceral lesion and at the site of drainage of liver abscess.

Urogenital tract amoebiasis derived from intestinal lesion can cause amoebic vulvovaginitis (*May's disease*), rectovesicle fistula and rectovaginal fistula.

Entamoeba histolytica infection is associated with malnutrition and stunting of growth.^[18]

Epidemiology

As of 2010 it caused about 55,000 deaths down from 68,000 in 1990.^[19] In older textbooks it is often stated that 10% of the world's population is infected with *Entamoeba histolytica*. It is now known that at least 90% of these infections are due to *E. dispar*. Nevertheless, this means that there are up to 50 million true *E. histolytica* infections and approximately seventy thousand die each year, mostly from liver abscesses or other complications. Although usually considered a tropical parasite, the first case reported (in 1875) was actually in St Petersburg in Russia, near the Arctic Circle.^[20] Infection is more common in warmer areas, but this is both because of poorer hygiene and the parasitic cysts surviving longer in warm moist conditions.^[15]

History

The most dramatic incident in the USA was the Chicago World's Fair outbreak in 1933 caused by contaminated drinking water; defective plumbing permitted sewage to contaminate water.^[21] There were 1,000 cases (with 58 deaths). In 1998 there was an outbreak of amoebiasis in the Republic of Georgia.^[22] Between 26 May and 3 September 1998, 177 cases were reported, including 71 cases of intestinal amoebiasis and 106 probable cases of liver abscess.

The Nicobarese people have attested to the medicinal properties found in *Glochidion calocarpum*, a plant common to India, saying that its bark and seed are most effective in curing abdominal disorders associated with amoebiasis.^[23]

References

- "Entamoebiasis - MeSH - NCBI". *www.ncbi.nlm.nih.gov*. Retrieved 2015-07-21.
- "Entamoebiasis". *mesh.kib.ki.se*. Retrieved 2015-07-21.
- Farrar, Jeremy; Hotez, Peter; Junghanss, Thomas; Kang, Gagandeep; Laloo, David; White, Nicholas J. (2013-10-26). *Manson's Tropical Diseases*. Elsevier Health Sciences. pp. 664–671. ISBN 9780702053061.
- Beeching, Nick; Gill, Geoff (2014-04-17). "19". *Lecture Notes: Tropical Medicine*. John Wiley & Sons. pp. 177–182. ISBN 9781118734568.
- Haque, Rashidul; Huston, Christopher D.; Hughes, Molly; Houghton, Eric; Petri, William A. (2003-04-17). "Amebiasis". *NEJM*. **348** (16): 1565–1573. doi:10.1056/NEJMra022710. Retrieved 2012-04-12.
- Atlas of Human Infectious Diseases, First Edition. Heiman F.L. Wertheim, Peter Horby and John P. Woodall., 2012, Blackwell Publishing Ltd.
- Nespola, Benoît; Betz, Valérie; Brunet, Julie; Gagnard, Jean-Charles; Krummel, Yves; Hansmann, Yves; Hannedouche, Thierry; Christmann, Daniel; Pfaff, Alexander W.; Filisetti, Denis; Pesson, Bernard; Abou-Bacar, Ahmed; Candolfi, Ermanno (2015). "First case of amebic liver abscess 22 years after the first occurrence". *Parasite*. **22**: 20. doi:10.1051/parasite/2015020. ISSN 1776-1042. PMID 26088504.
- Day, David W.; Basil C. Morson; Jeremy R. Jass; Geraint Williams; Ashley B. Price (2003). *Morson and Dawson's Gastrointestinal Pathology*. John Wiley & Sons, Inc. ISBN 978-0-632-04204-3.
- "Foodborne Pathogenic Microorganisms and Natural Toxins Handbook: Entamoeba histolytica". *Bad Bug Book*. United States Food and Drug Administration: Center for Food Safety & Applied Nutrition. 2007-12-28. Archived from the original on 9 July 2009. Retrieved 2009-07-13.
- Berger SA, Marr JS. Human Parasitic Diseases Sourcebook. Jones and Bartlett Publishers: Sudbury, Massachusetts, 2006.
- Visvesvara GS, Moura H, Schuster FL (June 2007). "Pathogenic and opportunistic free-living amoebae: Acanthamoeba spp., Balamuthia mandrillaris, Naegleria fowleri, and Sappinia diploidea". *FEMS Immunol. Med. Microbiol.* **50** (1): 1–26. doi:10.1111/j.1574-695X.2007.00232.x. PMID 17428307.
- "Orphanet: Amoebiasis due to free living amoebae". Retrieved 2009-01-17. at Orphanet
- "EyeRounds.org:Acanthamoeba Keratitis: 39-year-old contact lens wearer with persisting keratitis & pain". Archived from the original on 5 December 2008. Retrieved 2009-01-17.
- Recavarren-Arce S, Velarde C, Gotuzzo E, Cabrera J (March 1999). "Amoeba angeitic lesions of the central nervous system in Balamuthia mandrilaris amoebiasis". *Hum. Pathol.* **30** (3): 269–73. doi:10.1016/S0046-8177(99)90004-7. PMID 10088544.
- Ryan KJ, Ray CG, eds. (2004). *Sherris Medical Microbiology* (4th ed.). McGraw Hill. pp. 733–8. ISBN 0-8385-8529-9.

16. Brock Biology of Microorganisms; Madigan (et al.); Pearson Education Inc., 2003; pgg. 947-948
17. "FDA Bacteriological Analytical Manual". Archived from the original on 6 April 2008. Retrieved 2008-03-26.
18. Mondal D, Petri Jr WA, Sack RB, et al. (2006). "*Entamoeba histolytica*-associated diarrheal illness is negatively associated with the growth of preschool children: evidence from a prospective study". *Trans R Soc Trop Med H.* **100** (11): 1032–38. doi:10.1016/j.trstmh.2005.12.012. PMID 16730764.
19. Lozano, R; Naghavi, M; Foreman, K; Lim, S; Shibuya, K; Aboyans, V; Abraham, J; Adair, T; Aggarwal, R; Ahn, SY; Alvarado, M; Anderson, HR; Anderson, LM; Andrews, KG; Atkinson, C; Baddour, LM; Barker-Collo, S; Bartels, DH; Bell, ML; Benjamin, EJ; Bennett, D; Bhalla, K; Bikbov, B; Bin Abdulhak, A; Birbeck, G; Blyth, F; Bolliger, I; Boufous, S; Bucello, C; et al. (Dec 15, 2012). "Global and regional mortality from 235 causes of death for 20 age groups in 1990 and 2010: a systematic analysis for the Global Burden of Disease Study 2010". *Lancet.* **380** (9859): 2095–128. doi:10.1016/S0140-6736(12)61728-0. PMID 23245604.
20. Lösch, F. (1875) Massenhafte Entwicklung von Amöben im Dickdarm. *Virchow's Archiv* 65: 196-211.
21. Markell EK (June 1986). "The 1933 Chicago outbreak of amebiasis". *West. J. Med.* **144** (6): 750. PMC 1306777 . PMID 3524005.
22. Kreidl P, Imnadze P, Baidoshvili L, Greco D (October 1999). "Investigation of an outbreak of amoebiasis in Georgia". *Euro Surveill.* **4** (10): 103–104. PMID 12631887.
23. See p. 412 in: Hammer, K (1990). "Barilla (*Salsola soda*, *Chenopodiaceae*)". *Economic Botany.* **44** (3): 410–412. Retrieved 22 December 2016 – via JSTOR. (registration required (help))).

External links

- *Amoebiasis* (<http://www.cdc.gov/parasites/amebiasis/>) - Centers for Disease Control and Prevention
- *Amoeba infection symptoms* (http://www.10humanparasites.info/amoeba_parasite_infection_symptoms.htm)

Retrieved from "<https://en.wikipedia.org/w/index.php?title=Amoebiasis&oldid=756134904>"

Categories: [Intestinal infectious diseases](#) | [Waterborne diseases](#)

- This page was last modified on 22 December 2016, at 06:03.
- Text is available under the Creative Commons Attribution-ShareAlike License; additional terms may apply. By using this site, you agree to the Terms of Use and Privacy Policy. Wikipedia® is a registered trademark of the Wikimedia Foundation, Inc., a non-profit organization.