

Anatomical terms of location

From Wikipedia, the free encyclopedia

Standard **anatomical terms of location** deal unambiguously with the anatomy of animals, including humans.

All vertebrates (including humans) have the same basic body plan – they are strictly bilaterally symmetrical in early embryonic stages and largely bilaterally symmetrical in adulthood.^[1] That is, they have mirror-image left and right halves if divided down the centre.^[2] For these reasons, the basic directional terms can be considered to be those used in vertebrates. By extension, the same terms are used for many other (invertebrate) organisms as well.

While these terms are standardized within specific fields of biology, there are unavoidable, sometimes dramatic, differences between some disciplines. For example, differences in terminology remain a problem that, to some extent, still separates the terminology of human anatomy from that used in the study of various other zoological categories.

Contents

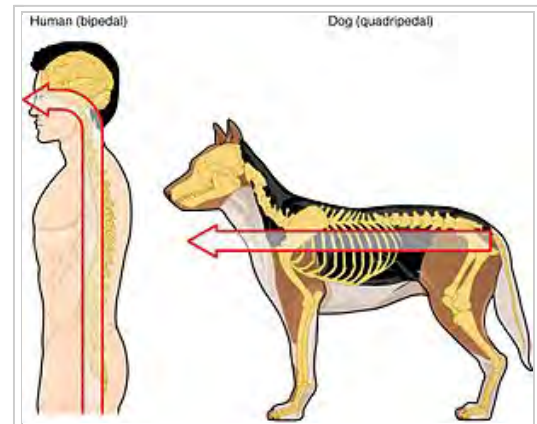
- 1 Introduction
 - 1.1 Standard anatomical position
 - 1.2 Combined terms
 - 1.3 Planes
 - 1.4 Axes
- 2 Main terms
 - 2.1 Superior and inferior
 - 2.2 Anterior and posterior
 - 2.3 Medial and lateral
 - 2.4 Proximal and distal
 - 2.4.1 Chemical & molecular physics
 - 2.5 Central and peripheral
 - 2.6 Superficial and deep
 - 2.7 Dorsal and ventral
 - 2.8 Cranial and caudal
- 3 Other terms and special cases
 - 3.1 Anatomical landmarks
 - 3.2 Mouth and teeth
 - 3.3 Hands and feet
 - 3.4 Rotational direction
 - 3.5 Other directional terms
- 4 Specific animals and other organisms
 - 4.1 Humans
 - 4.2 Asymmetrical and spherical organisms
 - 4.3 Elongated organisms
 - 4.4 Radially symmetrical organisms
 - 4.5 Spiders
- 5 Citations
- 6 Sources
- 7 See also

Introduction

Standardized anatomical and zoological terms of location have been developed, usually based on Latin and Greek words, to enable all biological and medical scientists to precisely delineate and communicate information about animal bodies and their component organs, even though the meaning of some of the terms often is context-sensitive.^[3]

The vertebrates and *Craniata* share a substantial heritage and common structure, so many of the same terms are used to describe location. To avoid ambiguities this terminology is based on the anatomy of each animal in a standard way.

For humans, one type of vertebrate, anatomical terms may differ from other forms of vertebrates. For one reason, this is because humans have a different neuraxis and, unlike animals that rest on four limbs, humans are considered when describing anatomy as being in the standard anatomical position. Thus what is on "top" of a human is the head, whereas the "top" of a dog may be its back, and the "top" of a flounder could refer to either its left or its right side.



Because of differences in the way humans and other animals are structured, different terms are used according to the neuraxis and whether an animal is a vertebrate or invertebrate.

For invertebrates, standard application of locational terminology often becomes difficult or debatable at best when the differences in morphology are so radical that common concepts are not homologous and do not refer to common concepts. For example, many species are not even bilaterally symmetrical. In these species, terminology depends on their type of symmetry (if any).

Standard anatomical position

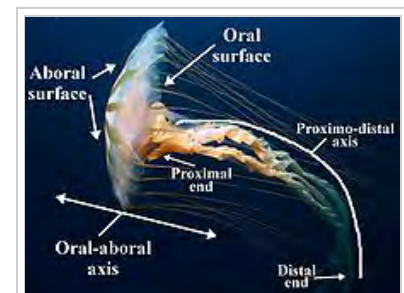Because animals can change orientation with respect to their environment, and because appendages like limbs and tentacles can change position with respect to the main body, positional descriptive terms need to refer to the animal as in its standard anatomical position. *All descriptions are with respect to the organism in its standard anatomical position*, even when the organism in question has appendages in another position. This helps avoid confusion in terminology when referring to the same organism in different postures.

In humans, this refers to the body in a standing position with arms at the side and palms facing forward (thumbs out). While the universal vertebrate terminology used in veterinary medicine would work in human medicine, the human terms are thought to be too well established to be worth changing.

Combined terms

Many anatomical terms can be combined, either to indicate a position in two axes simultaneously or to indicate the direction of a movement relative to the body. For example, "anterolateral" indicates a position that is both anterior and lateral to the body axis (such as the bulk of the pectoralis major muscle). In radiology, an X-ray image may be said to be "anteroposterior", indicating that the beam of X-rays pass from their source to patient's anterior body wall through the body to exit through posterior body wall.^[4]

There is no definite limit to the contexts in which terms may be modified to qualify each other in such combinations. Generally the modifier term is truncated and an "o" or an "i" is added in prefixing it to the qualified term. For example, a view of an animal from an aspect at once dorsal and lateral might be called a "dorsolateral" view; and the effect of dorsolateral flattening in an organism such as a krait gives its body a triangular cross section. Again, in describing the morphology of an organ or habitus of an animal such as many of the Platyhelminthes, one might speak of it as **dorsiventrally** flattened as opposed to bilaterally flattened animals such as ocean sunfish.



A jellyfish of the *Chrysaora* species. Like other animals, its appendages move, and in this image are not in a standard anatomical position. In anatomical position, the proximodistal axis (labelled) is straight, and the point labelled "distal end" neither to the left or the right of the jellyfishes' main axis.

Where desirable three or more terms may be agglutinated or concatenated, as in "anteriodorsolateral". Such terms sometimes used to be hyphenated, but the modern tendency is to omit the hyphen. There is however little basis for any strict rule to interfere with choice of convenience in such usage.^[5]

Planes

Three basic reference planes are used to describe location.

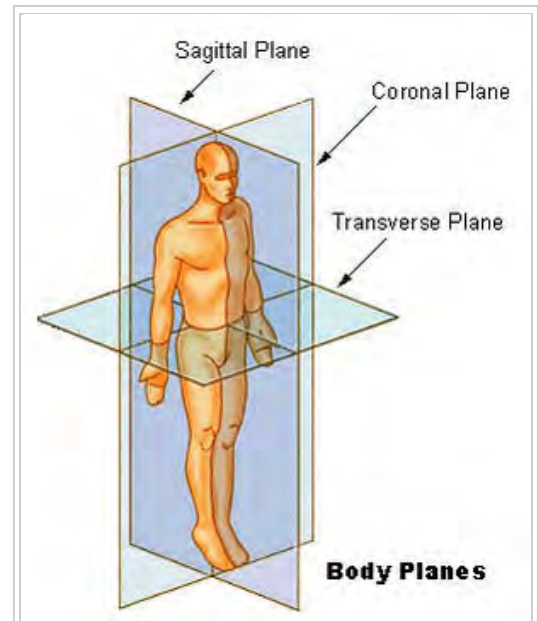
- The **sagittal plane** is a plane parallel to the sagittal suture. All other sagittal planes (referred to as *parasagittal planes*) are parallel to it. It is also known as a "longitudinal plane".^[6] The plane is a Y-Z plane, perpendicular to the ground.
- The **median plane** or **midsagittal plane** is in the midline of the body, and divides the body into left and right (sinister and dexter) portions.^[6] This passes through the head, spinal cord, navel and, in animals, the tail.^[6] The median plane can also refer to the midsagittal plane of other structures, such as a digit.
- The **frontal plane** or **coronal plane** divides the body into dorsal and ventral (back and front, or posterior and anterior) portions. For post-embryonic humans a coronal plane is vertical and a transverse plane is horizontal, but for embryos and quadrupeds a coronal plane is horizontal and a transverse plane is vertical. A *longitudinal plane* is any plane perpendicular to the transverse plane. The coronal plane and the sagittal plane are examples of *longitudinal planes*.
- A **transverse plane**, also known as a *cross-section*, divides the body into cranial and caudal (head and tail) portions.

In human anatomy

- A **transverse** (also known as **horizontal**) plane is an X-Y plane, parallel to the ground, which (in humans) separates the superior from the inferior or, put another way, the head from the feet.
- A **coronal** (also known as **frontal**) plane is a X-Z plane, perpendicular to the ground, which (in humans) separates the anterior from the posterior, the front from the back, the ventral from the dorsal.



Dorsolateral flattening in the anatomy of a krait gives its body a triangular cross-section



Anatomical planes in a human

Axes

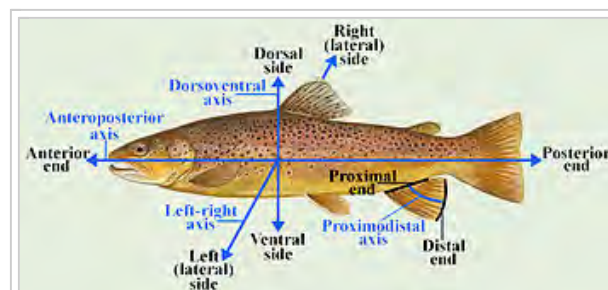


Figure 2: Anatomical directions and defined axes in a vertebrate

Defined axes in vertebrate zoology

Axis	Directional term	Directed towards
Anteroposterior (rostrocaudal ¹ , craniocaudal ¹ , cephalocaudal ²)	Anterior	Head end
	Posterior	Rear/tail end
Dorsoventral	Dorsal	Back, spinal column
	Ventral	Belly
Left-right (dextro-sinister ² , sinistro-dexter ²)	Left (sinister)	Left-hand side
	Right (dexter)	Right-hand side
Mediolateral ³	Medial	Centre
	Lateral	Left and right
Proximal/distal	Proximal	Point at which appendage joins the body
	Distal	Extremity of appendage

Notes:

(1) Fairly common use.

(2) Uncommon use.

(3) Equivalent to one-half of the left-right axis.

(The terms "intermediate", "ipsilateral", "contralateral", "superficial", and "deep", while indicating directions, are relative terms and thus do not properly define fixed anatomical axes. Also, while the "rostrocaudal" and anteroposterior directionality are equivalent in a significant portion of the human body, they are different directions in other parts of the body.)

To begin with, distinct, polar-opposite ends of the organism are chosen. By definition, each pair of opposite points defines an **axis**. In a bilaterally symmetrical organism, there are 6 polar opposite points, giving three axes that intersect at right angles – the x, y, and z axes familiar from three-dimensional geometry.

Main terms

Superior and inferior

In anatomical terminology **superior** (from Latin, meaning "above") is used to refer to what is above something, and **inferior** (from Latin, meaning "below") to what is below it. For example, in the anatomical position the most superior part of the human body is the head, and the most inferior is the feet.^{[7][8]} As a second example, in humans the neck is superior to the chest but inferior to the head.

Anterior and posterior

Anterior refers to what is in front (from Latin *ante*, meaning "before") and **posterior**, what is to the back of the subject (from Latin *post*, meaning "after").^[9] For example, in a dog the nose is anterior to the eyes and the tail is considered the most posterior part; in many fish the gill openings are posterior to the eyes, but anterior to the tail.

Medial and lateral

Lateral (from Latin *lateralis*, meaning "to the side") refers to the sides of an animal, as in "left lateral" and "right lateral". The term **medial** (from Latin *medius*, meaning "middle") is used to refer to structures close to the centre of an organism, called the "median plane".^[2] For example, in a fish the gills are medial to the operculum, but lateral to the heart.

The terms "left" and "right" are sometimes used, or their Latin alternatives (Latin: *dexter*; "right", Latin: *sinister*; "left"). However, as left and right sides are mirror images, using these words is somewhat confusing, as structures are duplicated on both sides. For example, it's very confusing to say the dorsal fin of a dolphin is "right of" the left pectoral fin, but is "left of" the right eye, but much easier and clearer to say "the dorsal fin is medial to the pectoral fins".

Derived terms include:

- **Contralateral** (from Latin *contra*, meaning "against"): on the side opposite to another structure. For example, the left arm is contralateral to the right arm, or the right leg.
- **Ipsilateral** (from Latin *ipse*, meaning "same"): on the same side as another structure. For example, the left arm is ipsilateral to the left leg.
- **Bilateral** (from Latin *bi*, meaning "two"): on both sides of the body. For example, bilateral orchiectomy (removal of testes on both sides of the body's axis) is surgical castration.
- **Unilateral** (from Latin *uni*, meaning "one"): on one side of the body. For example, unilateral paresis is hemiparesis.

These terms are commonly used in neuroanatomy, due to the layout of the nervous system. For example, the motor cortex of the right brain controls movement of the contralateral left arm.

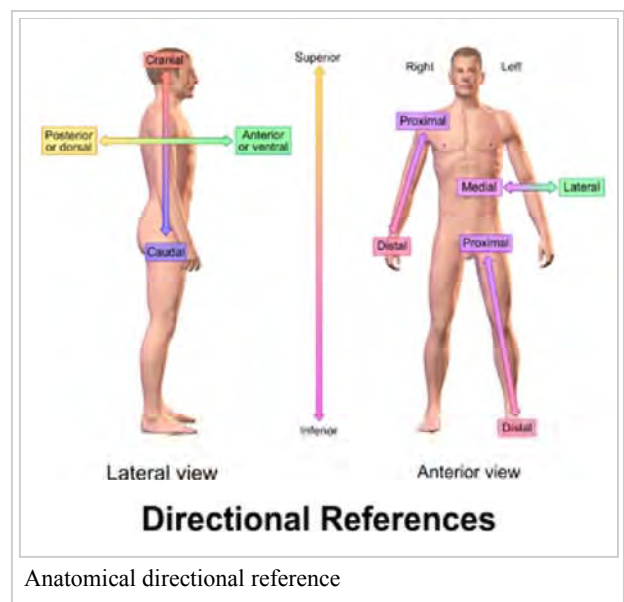
Proximal and distal

The terms **proximal** (from Latin *proximus*, meaning "nearest") and **distal** (from Latin *distare*, meaning "to stand away from") are used to describe parts of a feature that are close to or distant from the main mass of the body, respectively.^[9] Thus the upper arm in humans is proximal and the hand is distal.

These terms are particularly useful when describing appendages such as fins, tentacles, limbs or indeed any structure that extends that can potentially move separately from the main body. Although the direction indicated by "proximal" and "distal" is always respectively towards or away from the point of attachment, a given structure can be either proximal or distal in relation to another point of reference. Thus the elbow is distal to a wound on the upper arm, but proximal to a wound on the lower arm.^[10]

Chemical & molecular physics

This terminology is also employed in molecular biology and therefore by extension is also used in chemistry. Specifically as referring to the atomic loci of molecules from the overall moiety of a given compound.^[11]



Central and peripheral

Central and **peripheral** are terms that are closely related to concepts such as proximal and distal, but they are so widely applicable that in many respects their flexibility makes them hard to define. Loosely speaking, they distinguish near and far, inside and out, or even organs of vital importance such as heart and lungs, from peripheral organs such as fingers, that undoubtedly may be important, but which it may not be life-threatening to dispense with. Examples of the application of the terms are the distinction between central- and peripheral nervous systems, and between peripheral blood vessels and the central circulatory organs, such as the heart and major vessels. The terms also can apply to large and complex molecules such as proteins, where central amino acid residues are protected from antibodies or the like, but peripheral residues are important in docking and other interactions. Other examples include *Central and peripheral circadian clocks*,^[12] and *central versus peripheral vision*.^[13]

Superficial and deep

These two terms relate to the distance of a structure from the surface of an animal.

Deep (from Old English) refers to something further away from the surface of the organism. For example, the external oblique muscle of the abdomen is deep to the skin. "Deep" is one of the few anatomical terms of location derived from Old English rather than Latin - the anglicised Latin term would have been "profound" (Latin: *profundus*, "due to depth").

Superficial (from Latin *superfacies*, meaning "at the surface") refers to something near the outer surface of the organism. For example, in skin the epidermis is superficial to the subcutis.

Dorsal and ventral

These two terms refer to front/belly (ventral) and back (dorsal) of an organism.

The **dorsal** (from Latin *dorsum*, meaning "back") surface of an organism refers to the back, or upper side, of an organism. If talking about the skull, the dorsal side is the top.^[14]

The **ventral** (from Latin *venter*, meaning "belly") surface refers to the front, or lower side, of an organism.^[14]

For example, in a fish the pectoral fins are dorsal to the anal fin, but ventral to the dorsal fin. These terms are not only used in anatomy but also in the study of embryology.

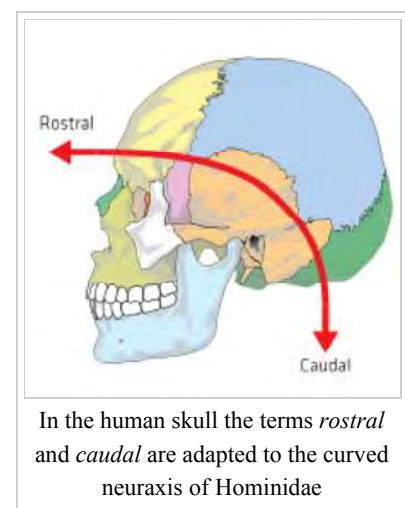
Cranial and caudal

Specific terms exist to describe how close or far something is to the head or tail of an animal. To describe how close to the head of an animal something is, three distinct terms are used:

- **Rostral**, from Latin *rōstrum* ("beak, nose"): situated toward the oral or nasal region, or in the case of the brain, toward the tip of the frontal lobe.
- **Cranial**, from Greek *κράνιον* (*kranion*, "skull") or **cephalic** (*κεφαλή* (*kephalē*, "head")).^[2]

To describe how close something is to the end of an organism, the term **caudal** is used (from Latin *cauda*, "tail"). In the horse, for example, the eyes are caudal to the nose and rostral to the back of the head.

These terms are generally preferred in veterinary medicine and not used as often in human medicine.^{[2][15][16]} In humans, "cranial" and "cephalic" are used to refer to the skull, with "cranial" being used more commonly. The term "rostral" is rarely used in human anatomy, apart from embryology, and refers more to the front of the



face than the superior aspect of the organism. Similarly, the term "caudal" is only occasionally used in human anatomy.^[8] This is because the brain is situated at the superior part of the head whereas the nose is situated in the anterior part. Thus the "rostrocaudal axis" refers to a C shape (see image).

Other terms and special cases

Anatomical landmarks

The location of anatomical structures can also be described with relation to different anatomical landmarks.

Structures may be described as being at the level of a specific spinal vertebra, depending on the section of the vertebral column the structure is at. The position is often abbreviated. For example, a structures at the level of the fourth cervical vertebra may be abbreviated as "C4", at the level of a thoracic vertebra "T4", at the level of a lumbar vertebra "L3". Because the sacrum is fused, it is not often used to provide location.

References may also take origin from superficial anatomy, made to landmarks that are on the skin or visible underneath. For example, structures may be described relative to the anterior superior iliac spine, the medial malleolus or the medial epicondyle.

Anatomical lines, theoretical lines drawn through structures, are also used to describe anatomical location. For example, the mid-clavicular line is used as part of the cardiac exam in medicine to feel the apex beat of the heart.

Mouth and teeth

Fields such as osteology, palaeontology and dentistry apply special terms of location to describe the mouth and teeth. This is because although teeth may be aligned with their main axes within the jaw, some different relationships require special terminology as well; for example teeth also can be rotated, and in such contexts terms like "anterior" or "lateral" become ambiguous.^{[17][18]} Terms such as "distal" and "proximal" are also redefined to mean the distance away or close to the mandibular symphysis. Terms used to describe structures include "buccal" (from Latin *bucca*, meaning "cheek") and "palatal" (from Latin) referring to structures close to the cheek and hard palate respectively.

Hands and feet

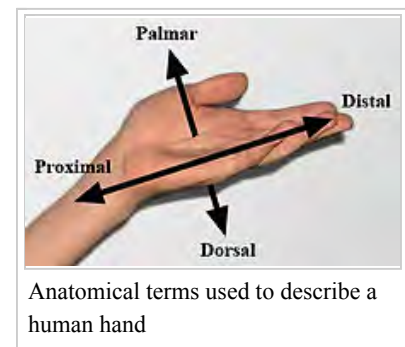
Several anatomical terms are particular to the hands and feet

For improved clarity, the directional term **palmar** (from Latin *palma*, meaning "palm of the hand") is usually used to describe the front of the hand, and **dorsal** is the back of the hand. For example, the top of a dog's paw is its dorsal surface; the underside, either the palmar (on the forelimb) or the plantar (on the hindlimb) surface. The palmar fascia is palmar to the tendons of muscles which flex the fingers, and the dorsal venous arch is so named because it is on the dorsal side of the foot.

Volar can also be used to refer to the underside of the palm or sole, which are themselves also sometimes used to describe location as *palmar* and *plantar*. For example, volar pads are those on the underside of hands, fingers, feet, and toes.

These terms are used to avoid confusion when describing the median surface of the hand and what is the "anterior" or "posterior" surface – "anterior" can be used to describe the palm of the hand, and "posterior" can be used to describe the back of the hand and arm. This confusion can arise because the forearm can pronate and supinate.

Similarly, in the forearm, for clarity, the sides are named after the bones. Structures closer to the radius are **radial**, structures closer to the ulna are **ulnar**, and structures relating to both bones are referred to as **radioulnar**. Similarly, in the lower leg, structures near the tibia (shinbone) are **tibial** and structures near the fibula are **fibular** (or **peroneal**).



Rotational direction

Most terms of anatomical location are relative to linear motion (translation) along the X- Y- and Z-axes, but there are other degrees of freedom as well, in particular, rotation around any of those three axes.

Anteversio and **retroversio** are complementary anatomical terms of location, describing the degree to which an anatomical structure is rotated forwards (towards the front of the body) or backwards (towards the back of the body) respectively, relative to some datum position. The terms also describe the positioning of surgical implants, such as in arthroplasty.

- **Anteversio** refers to an anatomical structure being tilted further *forward* than normal, whether pathologically or incidentally. For example, there may be a need to measure the anteversion of the neck of a bone such as a femur.^[19] For example, a woman's uterus typically is anteverted, tilted slightly *forward*. A misaligned pelvis may be anteverted, that is to say tilted *forward* to some relevant degree.
- **Retroversio** is rotation around the same axis as that of anteversion, but in the opposite sense, that is to say, tilting *back*. A structure so affected is described as being retroverted. As with anteversion, retroversion is a completely general term and can apply to a backward tilting of such hard structures as bones, soft organs such as uteri, or surgical implants.

Other directional terms

Several other terms are also used to describe location. These terms are not used to form the fixed axes. Terms include:

- **Axial** (from Latin *axōn*, meaning "axle"): around the central axis of the organism or the extremity. Two related terms, "abaxial" and "adaxial", refer to locations away and toward the central axis of an organism, respectively.
- **Intermediate** (from Latin *inter*, meaning "between", and Latin *medius*, meaning "middle"): between two other structures. For example, the navel is intermediate to the left arm and the contralateral (right) leg.
- **Parietal** (from Latin *paries*, meaning "wall"): pertaining to the wall of a body cavity. For example, the parietal peritoneum is the lining on the inside of the abdominal cavity. Parietal can also refer specifically to the parietal bone of the skull or associated structures.
- **Visceral** (from Latin *viscus*, meaning "internal organs"): associated with organs within the body's cavities. For example, the stomach is covered with a lining called the visceral peritoneum. Viscus can also be used to mean "organ". For example, the stomach is a viscus within the abdominal cavity.

Latin convention

Commonly when, for example, one anatomical feature is nearer to something than another, one may use an expression such as "nearer the distal end" or "distal to". However, an unambiguous and concise convention is to use the Latin suffix *-ad*, meaning "towards", or sometimes "to".^[9] So for example, "*distad*" means "in the distal direction", and "*distad of the femur*" means "beyond the femur in the distal direction". The suffix may be used very widely, as in the following examples: *anteriad* (towards the anterior), *apicad* (towards the apex), *basad* (towards the basal end), *caudad*, *centrad*, *cephalad* (towards the cephalic end), *craniad*, *dextrad*, *dextrocaudad*, *dextrocephalad*, *distad*, *dorsad*, *ectad* (towards the ectal, or exterior, direction), *entad* (towards the interior), *laterad*, *mediad*, *mesad*, *neurad*, *orad*, *posteriad*, *proximad*, *rostrad*, *sinistrad*, *sinistrocaudad*, *sinistrocephalad*, *ventrad*.^[20]

Specific animals and other organisms

The large variety of body shapes present in invertebrates presents a difficult problem when attempting to apply standard directional terms. Depending on the organism, some terms are taken by analogy from vertebrate anatomy, and appropriate novel terms are applied as needed. Some such borrowed terms are widely applicable in most invertebrates; for example proximal, literally meaning "near" refers to the part of an appendage nearest to where it joins the body, and distal, literally meaning "standing away from" is used for the part furthest from the point of attachment. In all cases, the usage of terms is dependent on the body plan of the organism.

For example, especially in organisms without distinct heads for reasons of broader applicability, "anterior" is usually

preferred.^{[2][15][16]}

Humans

As humans are approximately bilaterally symmetrical organisms,^[1] anatomical descriptions usually use the same terms as those for vertebrates and other members of the taxonomic group Bilateria. However, for historical and other reasons, standard human directional terminology has several differences from that used for other bilaterally symmetrical organisms.

The terms of zootomy and anatomy came into use at a time when all scientific communication took place in Latin. In their original Latin forms the respective meanings of "anterior" and "posterior" are *in front of* (or *before*) and *behind* (or *after*), those of "dorsal" and "ventral" are *toward the spine* and *toward the belly*, and those of "superior" and "inferior" are *above* and *below*.

Humans, however, have the rare property of having an upright torso. This makes their anterior/posterior and dorsal/ventral directions the same, and the inferior/superior directions necessary.^[21]

Most animals, furthermore, are capable of moving relative to their environment. So while "up" might refer to the direction of a standing human's head, the same term ("up") might be used to refer to the direction of the belly of a supine human. It is also necessary to employ some specific anatomical knowledge in order to apply the terminology unambiguously: For example, while the ears would be *superior* to (above) the shoulders in a human, this fails when describing the armadillo, where the shoulders are above the ears. Thus, in veterinary terminology, the ears would be *cranial* to (i.e., "toward the head from") the shoulders in the armadillo, the dog, the kangaroo, or any other terrestrial vertebrate, including the human. Likewise, while the belly is considered *anterior* to (in front of) the back in humans, this terminology fails for the flounder, the armadillo, and the dog. In veterinary terms, the belly would be *ventral* ("toward the abdomen") in all vertebrates.

While it would be possible to introduce a system of axes that is completely consistent between humans and other vertebrates by having two separate pairs of axes, one used exclusively for the head (e.g., anterior/posterior and inferior/superior) and the other exclusively for the torso (e.g., dorsal/ventral and caudal/rostral, or "toward the tail"/"toward the beak"), doing so would require the renaming of many anatomical structures.

Asymmetrical and spherical organisms

In organisms with a changeable shape, such as amoeboid organisms, most directional terms are meaningless, since the shape of the organism is not constant and no distinct axes are fixed. Similarly, in spherically symmetrical organisms, there is nothing to distinguish one line through the centre of the organism from any other. An indefinite number of triads of mutually perpendicular axes could be defined, but any such choice of axes would be useless, as nothing would distinguish a chosen triad from any others. In such organisms, only terms such as *superficial* and *deep*, or sometimes *proximal* and *distal*, are usefully descriptive.

Elongated organisms

In organisms that maintain a constant shape and have one dimension longer than the other, at least two directional terms can be used. The *long* or *longitudinal axis* is defined by points at the opposite ends of the organism.

Similarly, a perpendicular *transverse axis* can be defined by points on opposite sides of the organism. There is typically no basis for the definition of a third axis. Usually such organisms are planktonic (free-swimming) protists, and are nearly always viewed on microscope slides, where they appear essentially two-dimensional. In some cases a third axis can be defined, particularly where a non-terminal cytostome or other unique structure is present.^[16]

Some elongated protists have distinctive ends of the body. In such organisms, the end with a mouth (or equivalent structure, such as the cytostome in *Paramecium* or *Stentor*), or the end that usually points in the direction of the organism's locomotion (such as the end with the flagellum in *Euglena*), is normally designated as the **anterior** end. The opposite end

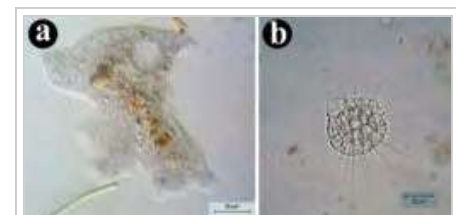


Figure 5: Asymmetrical and spherical body shapes. (a) An organism with an asymmetrical, amoeboid, body plan (*Amoeba proteus* – an amoeba). (b) An organism with a spherical body plan (*Actinophrys sol* – a heliozoan).

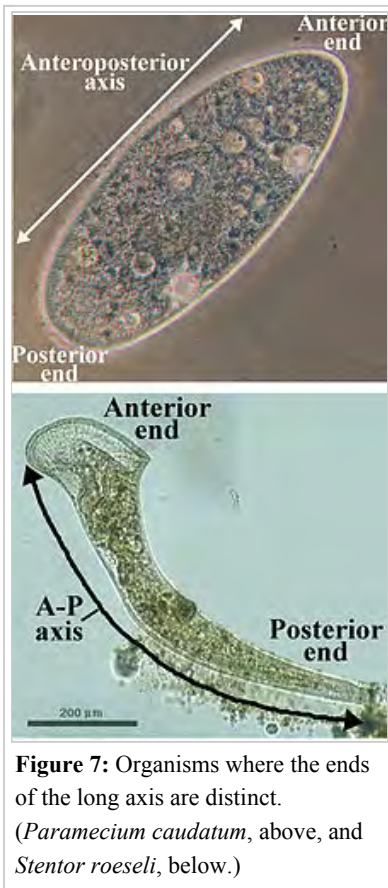


Figure 7: Organisms where the ends of the long axis are distinct. (*Paramecium caudatum*, above, and *Stentor roeseli*, below.)

then becomes the **posterior end**.^[16] Properly, this terminology would apply only to an organism that is always planktonic (not normally attached to a surface), although the term can also be applied to one that is sessile (normally attached to a surface).^[22]

Organisms that are attached to a substrate, such as sponges, or some animal-like protists also have distinctive ends. The part of the organism attached to the substrate is usually referred to as the **basal end** (Latin: *basis*, "support/foundation"), whereas the end furthest from the attachment is referred to as the **apical end** (Latin: *apex*, "peak/tip").

Radially symmetrical organisms

Radially symmetrical organisms include those in the group Radiata – primarily jellyfish, sea anemones and corals and the comb jellies.^{[2][16]} Adult echinoderms, such as starfish, sea urchins, sea cucumbers and others are also included, since they are pentaradial, meaning they have five discrete rotational symmetry. Echinoderm larvae are

not included, since they are bilaterally symmetrical.^{[2][16]} Radially symmetrical organisms always have one distinctive axis.

Cnidarians (jellyfish, sea anemones and corals) have an incomplete digestive system, meaning that one end of the organism has a mouth, and the opposite end has no opening from the gut (coelenteron).^[16] For this reason, the end of the organism with the mouth is referred to as the **oral end** (Latin: *oris*, "mouth"), and the opposite surface is the **aboral end** (Latin: *ab-*, prefix meaning "away from").

Unlike vertebrates, cnidarians have no other distinctive axes. "Lateral", "dorsal", and "ventral" have no meaning in such organisms, and all can be replaced by the generic term **peripheral** (Latin: *peri-*, "around"). **Medial** can be used, but in the case of radiates indicates the central point, rather than a central axis as in vertebrates. Thus, there are multiple possible **radial axes** and **medio-peripheral** (half-) **axes**. However, it is noteworthy that some biradially symmetrical comb jellies do have distinct "tentacular" and "pharyngeal" axes^[23] and are thus anatomically equivalent to bilaterally symmetrical animals.

As with vertebrates, appendages that move independently of the body (tentacles in cnidarians and comb jellies), have a definite *proximodistal axis* (Fig. 9).

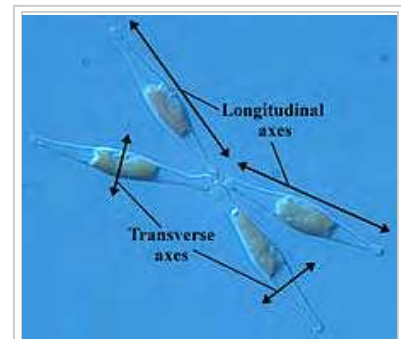


Figure 6: Four individuals of *Phaeodactylum tricorutum*, a diatom with a fixed elongated shape.



Figure 8: A cluster of *Euplectella aspergillum* sponges (Venus flower baskets), showing the apical-basal axes.

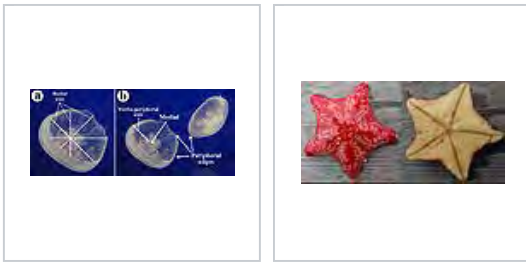

Figure 10: *Aurelia aurita*, another species of jellyfish, showing multiple radial and medio-peripheral axes

The sea star *Porania pulvillus*, aboral and oral surfaces


Spiders

Two specialized terms are useful in describing views of arachnid legs and pedipalps. **Prolateral** refers to the surface of a leg that is closest to the anterior end of an arachnid's body. **Retrolateral** refers to the surface of a leg that is closest to the posterior end of an arachnid's body.^[24]

Because of the unusual nature and positions of the eyes of the Araneae (spiders), and their importance in taxonomy, evolution and anatomy, special terminology with associated abbreviations has become established in arachnology. Araneae normally have eight eyes in four pairs. All the eyes are on the carapace of the prosoma, and their sizes, shapes and locations are characteristic of various spider families and other taxa. In some taxa not all four pairs of eyes are present, the relevant species having only three, two, or one pair of eyes. Some species (mainly troglobites) have no functional eyes at all.

In what is seen as the likeliest ancestral arrangement of the eyes of the Araneae, there are two roughly parallel, horizontal, symmetrical, transverse rows of eyes, each containing two symmetrically placed pairs, respectively called: anterior and posterior lateral eyes (ALE) and (PLE); and anterior and posterior median eyes (AME) and (PME).

As a rule it is not difficult to guess which eyes are which in a living or preserved specimen, but sometimes it can be. Apart from the fact that in some species one or more pairs may be missing, sometimes eyes from the posterior and anterior rows may be very close to each other, or even fused. Also, either one row or both might be so grossly curved that some of the notionally anterior eyes actually may lie posterior to some of the eyes in the posterior row. In some species the curve is so gross that the eyes apparently are arranged into two anteroposterior parallel rows of eyes.



Aspects of spider anatomy; This aspect shows the mainly prolateral surface of the anterior femora, plus the typical horizontal eye pattern of the Sparassidae

Typical arrangement of eyes in the Lycosidae, with PME being the largest

In the Salticidae the AME are the largest

Citations

- Wake 1992, p. 1.
- Hickman, C. P., Jr., Roberts, L. S. and Larson, A. *Animal Diversity*. McGraw-Hill 2003 ISBN 0-07-234903-4
- David Craigie (1838). *Elements of Anatomy, General, Special, and Comparative*. A. and C. Black.
- Dorland's Medical Dictionary for Health Consumers*. 2007 by Saunders, an imprint of Elsevier, Inc.
- "dorsolateral". Merriam-Webster.
- Wake 1992, p. 6.
- Marieb, E. N. (1995). *Human Anatomy and Physiology*. Benjamin Cummings. ISBN 0-8053-4281-8.
- Tortora, G. J.; Derrickson, B. (2006). *Principles of Anatomy and Physiology*. John Wiley & Sons. ISBN 0-471-68934-3.
- Wake 1992, p. 5.
- "What Do Distal and Proximal Mean?". *The Survival Doctor*. Retrieved 2016-01-07.
- Chemistry, Design, and Structure-Activity Relationship of Cocaine Antagonists. Page 990 (66th of article) (<https://www.erowid.org/archive/rhodium/pdf/cocaineanalogs&page#1,000> (76th of article) (<https://www.erowid.org/archive/rhodium/pdf/cocaineanalogs> Satendra Singh et al. Chem. Rev. 2000, 100. 925-1024. PubMed; Chemical Reviews (Impact Factor: 45.66). 04/2000; 100(3):925-1024 American Chemical Society; 2000. ISSN 0009-2665 (<https://www.worldcat.org/search?fq=x0:jnrl&q=n2:0009-2665>) ChemInform; May, 16th 2000, Volume 31, Issue 20, doi:10.1002/chin.200020238 (<https://dx.doi.org/10.1002%2Fchin.200020238>])
- Mohawk JA1, Green CB, Takahashi JS. Central and peripheral circadian clocks in mammals. *Annu Rev Neurosci*. 2012;35:445-62. doi: 10.1146/annurev-neuro-060909-153128. Epub 2012 Apr 5
- Adam M. Larson; Lester C. Loschky. The contributions of central versus peripheral vision to scene gist recognition. *Journal of Vision* September 2009, Vol.9, 6. doi:10.1167/9.10.6
- GO 2014, "dorsal/ventral axis specification" (GO:0009950).
- Miller, S. A. *General Zoology Laboratory Manual* McGraw-Hill, ISBN 0-07-252837-0 and ISBN 0-07-243559-3
- Ruppert, E. E., Fox, R. S. and Barnes, R. D. *Invertebrate Zoology: A Functional Evolutionary Approach*. Thomson, Belmont, 2004. ISBN 0-03-025982-7
- Pieter A. Folkens (2000). *Human Osteology*. Gulf Professional Publishing. pp. 558-. ISBN 978-0-12-746612-5.
- Smith, J. B.; Dodson, P. (2003). "A proposal for a standard terminology of anatomical notation and orientation in fossil vertebrate dentitions". *Journal of Vertebrate Paleontology*. **23** (1): 1–12. doi:10.1671/0272-4634(2003)23[1:APFAST] 2.0.CO;2.
- <http://informahealthcare.com/doi/abs/10.3109/02841858909journalCode=ard> Evaluation of Three Methods for Measurement of Femoral Neck Anteversion Femoral neck anteversion, definition, measuring methods and errors 1989, Vol. 30, No. 1, Pages 69-73 by Arne Høiseth1†, O. Reikerås1 and E. Fønstelien
- Gordh, Gordon; Headrick, David H (2011). *A Dictionary of Entomology* (2nd ed.). CABI. ISBN 978-1845935429.
- Tucker, T. G. (1931). *A Concise Etymological Dictionary of Latin*. Halle (Saale): Max Niemeyer Verlag.
- Valentine, James W. (2004). *On the Origin of Phyla*. Chicago: University of Chicago Press. ISBN 0-226-84548-6.
- Ruppert *et al.* (2004), p. 184.
- Kaston, B. J. (1972). *How to Know the Spiders* (2nd ed.). Dubuque, Iowa: W. C. Brown Co. p. 19. ISBN 0-697-04899-3.

Sources

- Wake, ed. by Marvale H. (1992). *Hyman's comparative vertebrate anatomy*. (3d ed.). Chicago: University of Chicago Press. ISBN 9780226870113.
- "GeneOntology". *GeneOntology*. The Gene Ontology Consortium. Retrieved 26 October 2014.

See also

- Standard anatomical position
- Anatomical terms of motion
- Anatomical terms of muscle
- Anatomical terms of bone
- Anatomical terms of neuroanatomy

Retrieved from "https://en.wikipedia.org/w/index.php?title=Anatomical_terms_of_location&oldid=755804172#Anterior_and_posterior"

Categories: Anatomy | Animal anatomy | Medical terminology | Orientation (geometry)

- This page was last modified on 20 December 2016, at 08:15.
- Text is available under the Creative Commons Attribution-ShareAlike License; additional terms may apply. By using this site, you agree to the Terms of Use and Privacy Policy. Wikipedia® is a registered trademark of the Wikimedia Foundation, Inc., a non-profit organization.