

AT MICROFICHE REFERENCE LIBRARY

A project of Volunteers in Asia

Simple Dental Care for Rural Hospitals

by: David J. Halestrap

Published by:

Medical Missionary Association
6 Canonbury Place
London, N1 2NJ
England

Paper copies are 0.50 British pounds. This text is not available for local reproduction in paper copies.

Available from:

Teaching Aids at Low Cost
Institute of Child Health
30, Guilford Street
London WC1N 1EH
England

Reproduced by permission of the Medical Missionary Association.

Reproduction of this microfiche document in any form is subject to the same restrictions as those of the original document.



**SIMPLE
DENTAL
CARE**

**for
Rural
Hospitals**

David J. Halestrap

Simple Dental Care for Rural Hospitals

DAVID J. HALESTRAP, B.D.S.

THE MEDICAL MISSIONARY ASSOCIATION
6 CANONBURY PLACE
LONDON, N1 2NJ

1971

© DAVID J. HALESTRAP

CONTENTS

Introduction	1
Acknowledgements	2
The Teeth and Gums	3
Diseases of the Teeth	5
Diseases of the Gums	7
Keeping the Teeth Clean	9
Treatment—Scaling the Teeth	11
Extracting Teeth—	
Injections	12
Method of Extracting Teeth	18
Broken Roots	20
Complications after Extraction	22
Other Dental Diseases	23
Conclusion	24
Practical Notes	25
A Dental Chair	26

INTRODUCTION

During a recent survey of dental work in some thirty church hospitals in rural areas of Uganda, Rwanda and Burundi it was found that each hospital saw between two and ten patients per week complaining of toothache, for which the only treatment provided was extraction. The extractions were often well performed by experienced para-medical workers, many of whom had had virtually no initial teaching, but had become proficient by practice. There were, however, only a few who felt really confident about the correct administration of local anaesthetics, and in some hospitals no attempt was made to provide local anaesthesia at all.

Furthermore, at each hospital many cases of gum disease were encountered for which little treatment was offered apart from extractions when the case was a severe one. The need for a simple treatment for such conditions was therefore indicated, as well as instruction in prophylactic measures.

Consequently, it was considered that the dental workers in many of these hospitals would benefit from some further instruction in simple dental work, so the author arranged to provide this by re-visiting some eighteen of them. Any necessary instruments were supplied where needed and an experimental edition of this booklet was used during the work in order to provide a background to, and reminder of, what was being taught. It has now been revised in the light of further experience, an attempt having been made to simplify the diagrams and to keep the vocabulary limited to enable an adequate comprehension by those for whom English is not their first language.

Its aim, therefore, is to offer a simple basic textbook for use in rural hospitals in developing countries, it being primarily for the benefit of the para-medical worker whose job it is to treat dental patients.

Mengo Hospital,
Kampala,
April 1970.

David J. Halestrap

ACKNOWLEDGEMENTS

My work in East Africa, including this booklet, would not have been possible unless the Church Missionary Society, and the Provincial Medical Board of the Church of Uganda had supported me. To them I am extremely grateful. A special word of appreciation goes to the Chairman of the Board, Dr. W. R. Billington, C.B.E., who originally conceived this project and has always been ready to provide valuable advice and encouragement.

I am indebted to the many kind individuals and to Christian Aid, the Rotary Club of Cirencester, the Anglican Church of Canada and the Christian Dental Fellowship of Britain for their generous financial assistance with the project. My gratitude is extended to Mr. J. L. Whitlock for his valuable work as treasurer as well as his provision of expert advice concerning a number of practicalities.

The advice of Mr. G. Scaif, Chief Dental Officer of Uganda, is gratefully acknowledged, and the constructive comments of Mr. A. S. Bisase about the contents of this book, based on his wide experience of African dentistry, have been much appreciated. Without the help and encouragement of Dr. H. H. W. Bennett of the Medical Missionary Association this book would not have been published. To him I owe a debt of gratitude as well as to Dr. D. Johnson of the Christian Medical Fellowship who was also instrumental in this enterprise.

Permission to reproduce the diagrams on page five is by kind permission of the General Dental Council of Great Britain. The photographs and several of the other illustrations were prepared by Mr. J. Busulwa and Mr. W. Serumaga of the Department of Medical Illustration, Makerere University, Kampala. To them I am very grateful, as well as to Dr. J. E. Tricker who helped prepare the anatomical diagrams and Miss J. Clark who designed the cover.

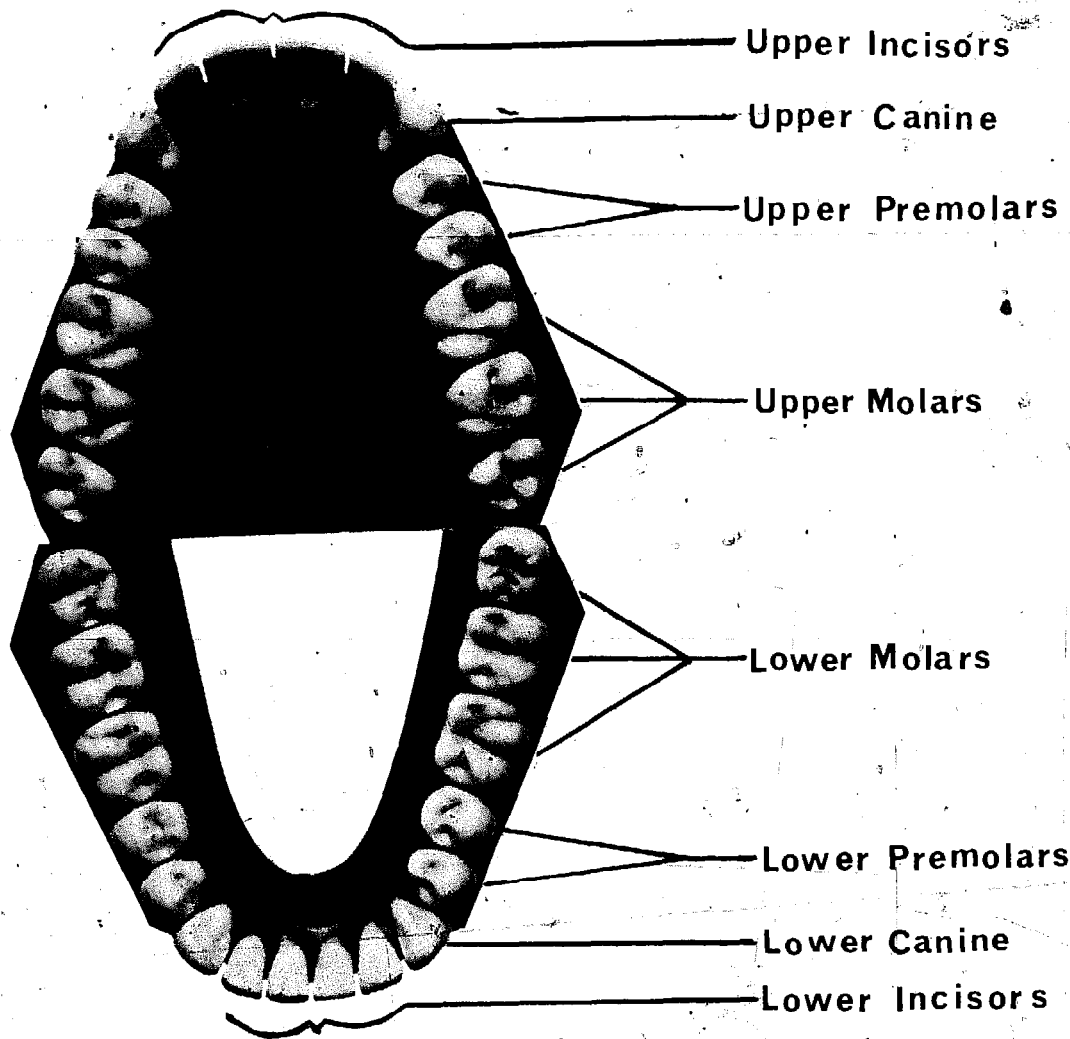
Finally, a word of thanks goes to all the doctors and other members of staff at the many hospitals who were so friendly and helpful during my recent visits.

D. J. H.

THE TEETH AND GUMS

FUNCTION OF THE TEETH

Food must be broken into small pieces in the mouth so that it can be swallowed easily, and to enable further digestion in the stomach to continue effectively. It is, therefore, important that the teeth are well cared for as well as the gums around them so that they have a good chance of being kept for a lifetime.



The teeth are arranged like this; there are four types.

1. Incisors: sharp front teeth
2. Canines: long pointed teeth
3. Premolars
4. Molars: back teeth for grinding food

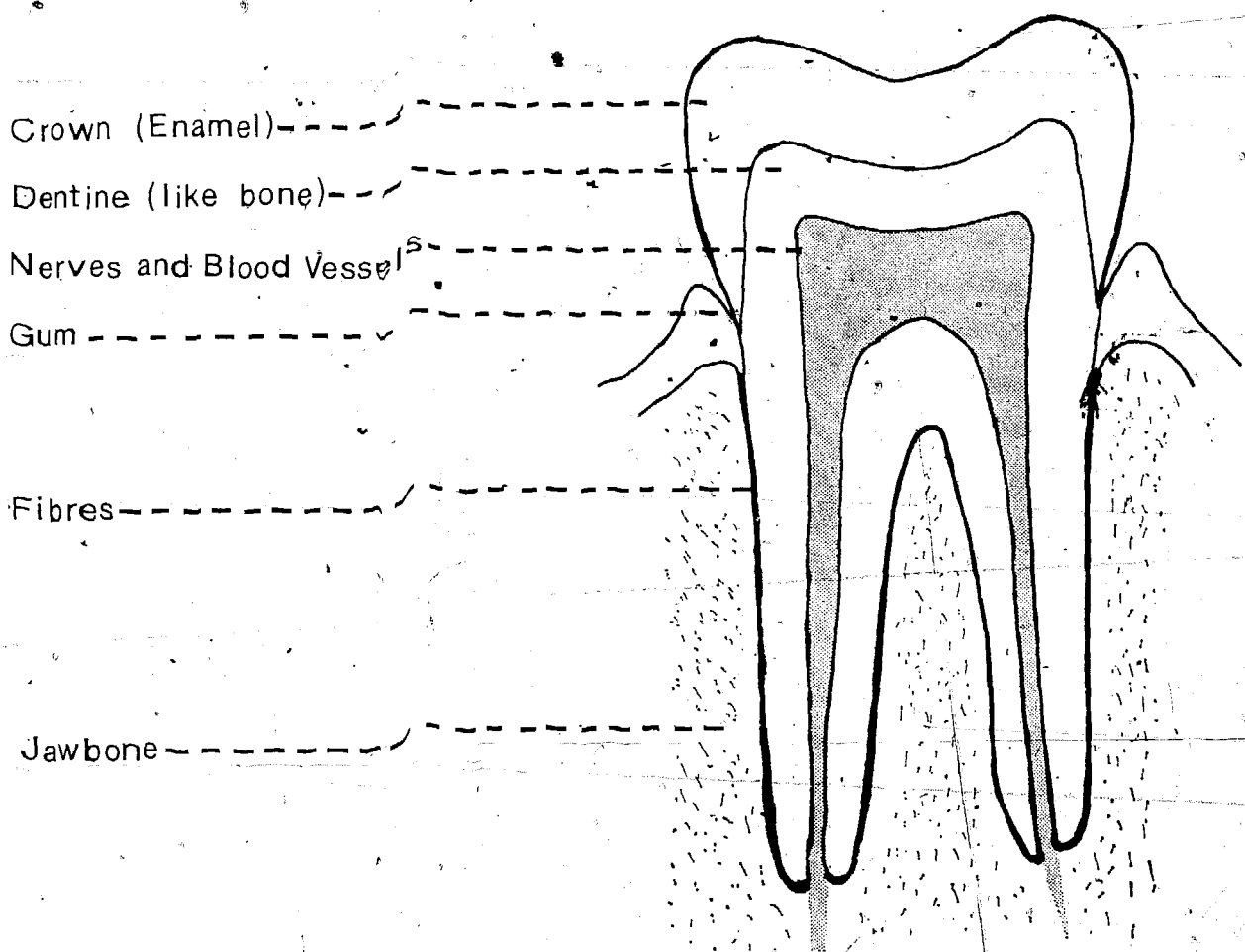
A fully grown person has *32 permanent teeth*.

The first of these teeth starts to come through the gum at 6 years of age and the last one after the age of 16.

A child has smaller teeth called "milk teeth" which start to be seen at the front of the mouth at 6 months of age. A child has a full set of 20 milk teeth when he is about 2 years old. When he is 6 years old he begins to lose them as the permanent teeth start to grow through the gum.

At this time the permanent teeth at the front of the mouth grow towards the gum causing the roots of the milk teeth to be eaten away so that they become loose and the child can pull them out. By about 12 years of age all the milk teeth have been lost in this way.

DIAGRAM OF A MOLAR TOOTH - Which has been cut down the middle

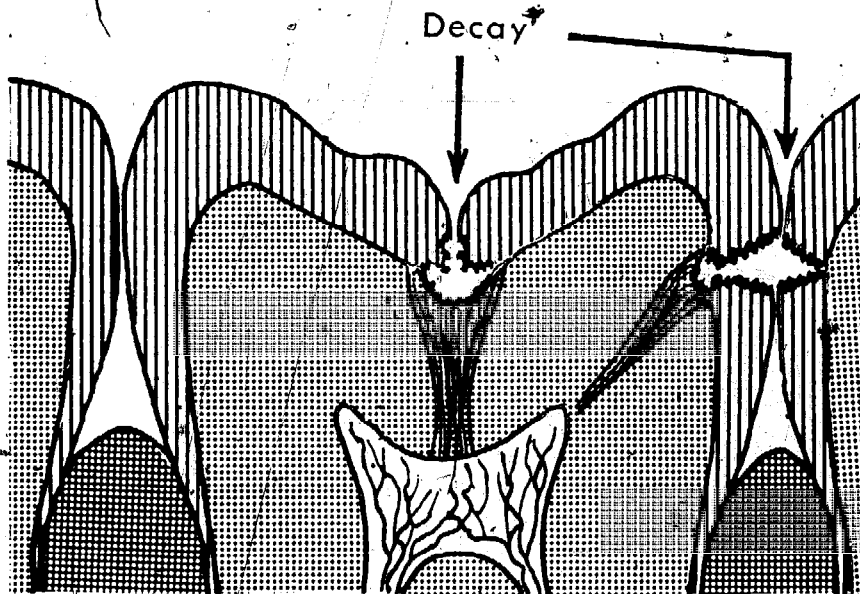
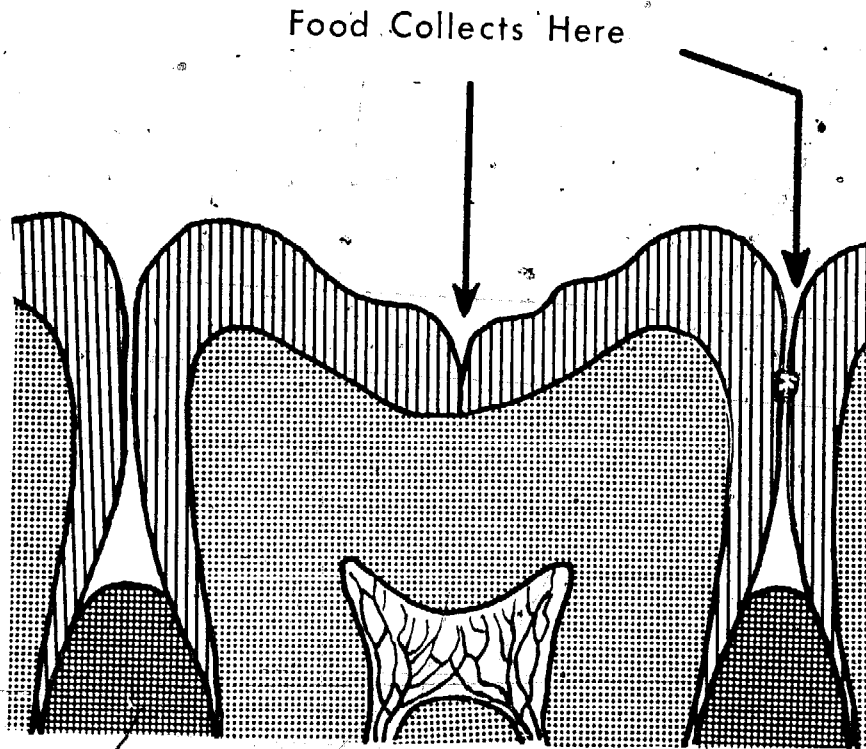


The outside of the crown of the tooth is very hard but inside it is softer, like bone, and right in the middle there is a small hole where nerves and blood vessels are found. These are connected to the larger vessels in the jawbone. The roots of the teeth are often longer than the crown which you see above the gum. Many thousands of very small fibres attach the root to its hole or socket in the jawbone. This is why teeth are firm and do not become loose when a hard piece of food is chewed.

DISEASES OF THE TEETH

DENTAL DECAY

Diagrams of the crowns of teeth which have been cut down the middle, to show how decay starts when food sticks to them.



HOW DENTAL DECAY STARTS

After each meal, food may remain in the cracks on the top of the teeth, or between the teeth. Bacteria eat this food and make an acid which dissolves a little bit of the tooth. A small hole therefore begins which will get bigger unless something is done to stop it. At this stage a dentist can remove the bad part of the tooth (decay) and place a *filling* in the hole. If this treatment is not carried out the hole will get bigger and as it gets nearer the nerve pain will be felt.

Symptoms of Decay

The pain will only be felt with hot, cold, sweet and acid foods at first, but later it will be felt all the time and will be severe. If the tooth is left untreated the decay will kill it and then an *abscess* may form. An abscess is an infection round the end of the root which has reached there from the decay in the crown of the tooth.

The symptoms of an abscess are:

1. The tooth hurts when it is knocked gently
2. There may be some swelling in the mouth next to the tooth
3. The whole side of the face may be swollen.

TREATMENT

If there is any swelling near the bad tooth it is usually advisable to give a course of antibiotics before giving a local anaesthetic. The doctor will tell you which one to give. When the swelling has gone down the tooth should be removed as soon as possible. If the extraction is not done the swelling and pain will come again. If there is no swelling and you are quite sure which tooth is causing the pain it may be extracted immediately. In a case where there is only a small hole and mild pain, and if the patient is very keen to keep the tooth, it may be possible to save it if the patient can reach a dentist.

If a general anaesthetic is used for tooth extractions it is not necessary to wait for the swelling of an abscess to go down before removing the offending tooth.

DISEASES OF THE GUMS

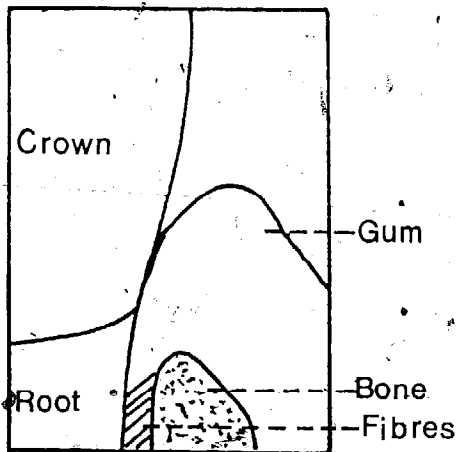
GINGIVITIS

This is the name given to inflammation of the gums. The patient complains of soreness and bleeding of the gums. It is usually caused by food being left around and between the teeth. If the patient does not keep his mouth clean this condition gets worse and spreads down towards the root, destroying the fibres attaching the tooth to the jaw. As this continues, the tooth begins to get loose and painful, and eventually it may be necessary to extract it. The condition is made worse by *tartar* (a hard substance which sticks to teeth that are not kept clean) which is most often seen behind the lower front teeth.

THE PROGRESS OF GUM DISEASE

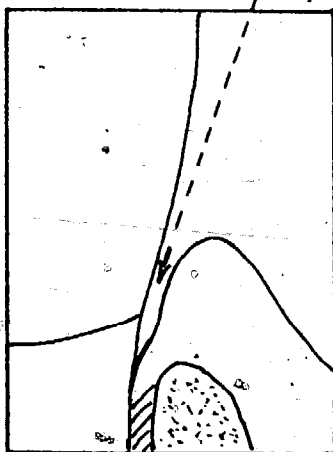
HEALTHY GUM

Gum attached to tooth



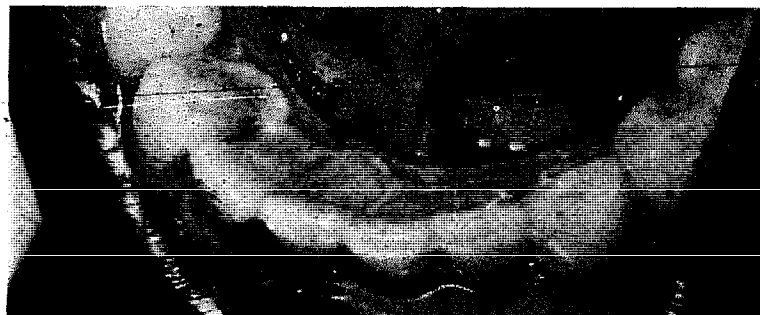
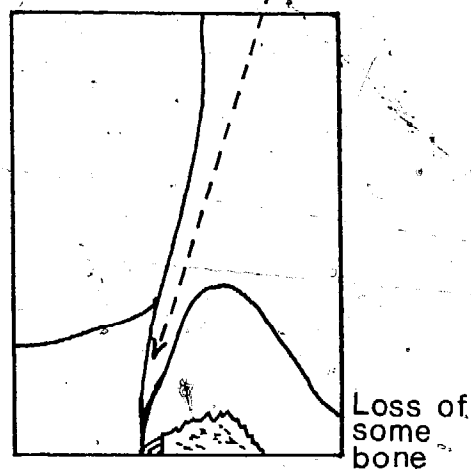
EARLY GINGIVITIS

Infection caused by food resting here, resulting in gap between tooth and gum.



SEVERE GUM DISEASE

Some fibres have been lost. Gap between tooth and gum getting bigger. Teeth may be loose and painful.



Tartar around the lower front teeth

Treatment.

If there is tartar present this should be removed (*scaling*) with a special instrument. When this has been done, or if tartar is not present, the patient should be taught how to brush the teeth correctly. Brushing the teeth properly prevents food resting on the gums and the inflammation (*gingivitis*) should improve.

ACUTE ULCERATIVE GINGIVITIS

This disease is not so widespread as simple gingivitis but is also found in people who do not keep their mouths clean. It is often seen in young children who do not have enough of the right foods to eat. It may also be seen in young adults.

Signs

Ulcers are seen along the margins of the gums, being next to one tooth or several. The mouth is very sore, and because of this the patient may not wish to eat. The ulcers which may have a white covering, bleed easily and the patient's breath has a characteristic smell. Sometimes the patient feels generally unwell and may have a slight temperature.

Treatment

Carefully apply a little 5% chromic acid or similar strong antiseptic on a very small piece of cotton wool to the ulcers. Do this once a day for outpatients, being careful not to allow the medicine to go anywhere else in the mouth, or on the skin because it is very strong and may burn. Tell the patient to keep the mouth clean. If it is too sore to use a brush, cotton wool or even a damp cloth may be used to wash the teeth. Rinsing the mouth with warm salt water after meals is also helpful. As soon as possible correct brushing with a toothbrush should be started. It is also important to ensure that the patient is having a good diet, especially if he is a child.

MALNUTRITION

The gums sometimes become red, swollen and painful in people who do not have enough of the right foods to eat, so it is important to make sure that patients with severe gingivitis are having a good balanced diet.

KEEPING THE TEETH CLEAN

Dental decay and gum disease are caused by food resting on the teeth and gums, so when a patient comes with bad teeth or gums it is important to teach him how to keep them clean so that he will not have so much trouble in the future. Often gingivitis can be completely cured by cleaning the teeth and gums correctly. Instruction in cleaning the teeth is for everyone, not only for those who already have dental disease. *Prevention is better than cure.* Teach those who do not have gum disease so they are less likely to get it. If you have children of your own, teach them. Teach anyone who wishes to have good health, but do teach them the proper way.

The toothbrush

A small toothbrush and toothpaste (dental cream) are the best means, but a stick (chewed at one end to make a brush) is quite good if it is used correctly. Common salt may be used on the stick or brush instead of toothpaste.

When to brush the teeth

After breakfast in the morning. It is no good brushing them before breakfast because you soon make them dirty again when you eat.

Before you go to bed at night. It is important that you sleep with a clean mouth.

If possible, after the midday meal, if you have one.

Method of cleaning teeth

Always start on the gum above or below the teeth and brush away from the gums over the teeth. When all the teeth have been cleaned like this brush the tops. Ensure that each surface of each tooth has been brushed at least ten times. This is not always easy, especially at the back of the mouth, and it will require practice. After a short time however, it will become easier but should take at least two minutes (*120 seconds!*). After brushing, the mouth should be thoroughly rinsed with water three times to wash away all the food that has been cleaned off the teeth.

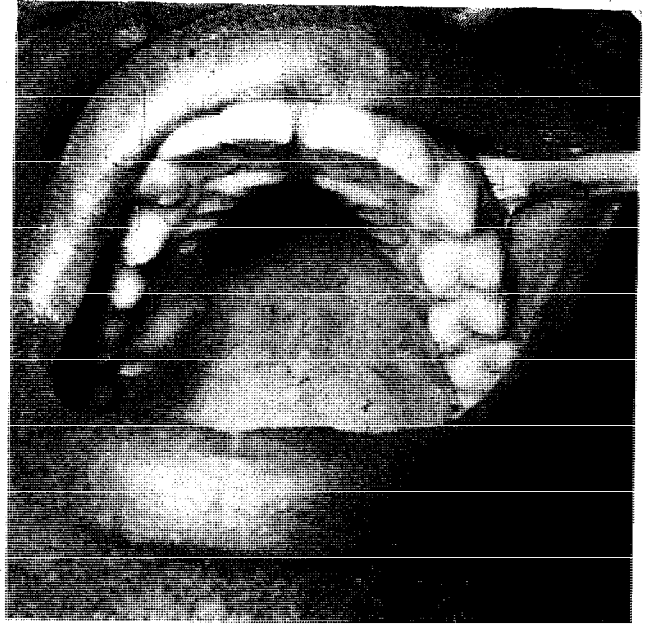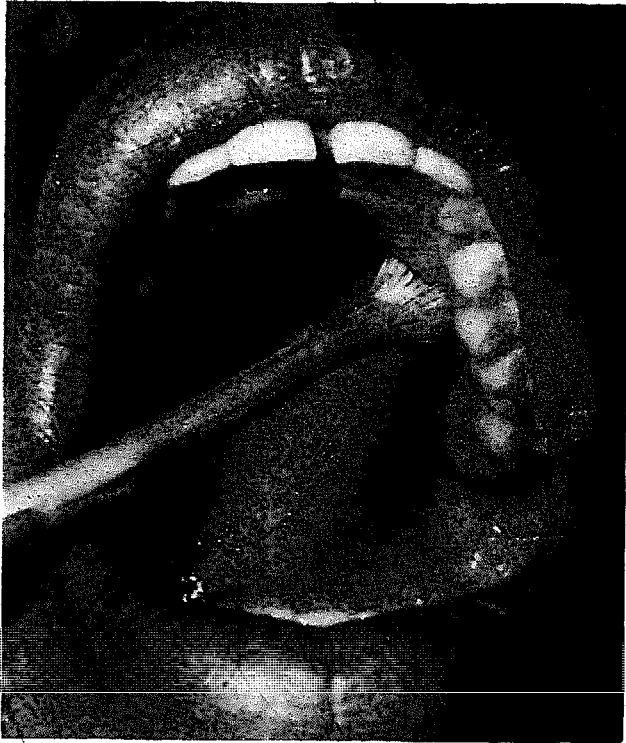
FOODS THAT ARE BAD FOR THE TEETH

These are ones which stick to the teeth and most of them contain a lot of sugar, such foods being cakes, biscuits and sweets. (This is why people who live in towns and eat European foods often have so many holes in their teeth.) If these foods are to be eaten they should be taken with meals because the teeth decay for half an hour after sweet foods have been in the mouth. If these foods are eaten between meals then the teeth will obviously be decaying for a longer time.

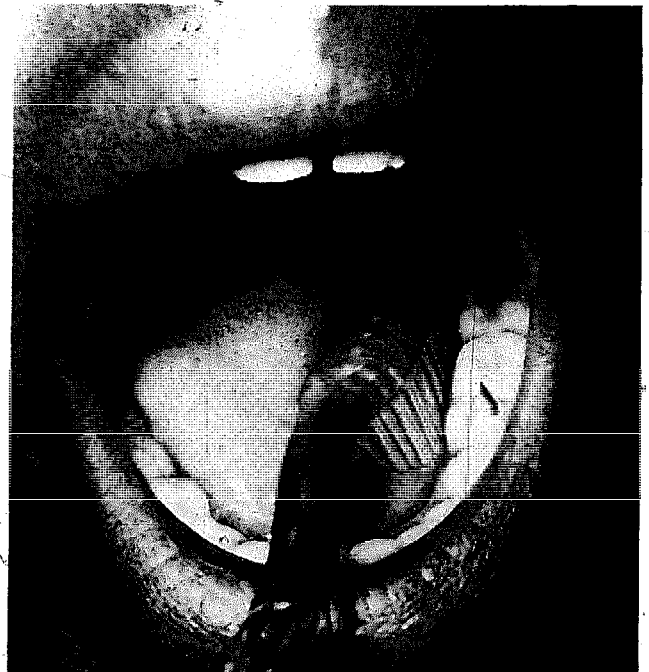
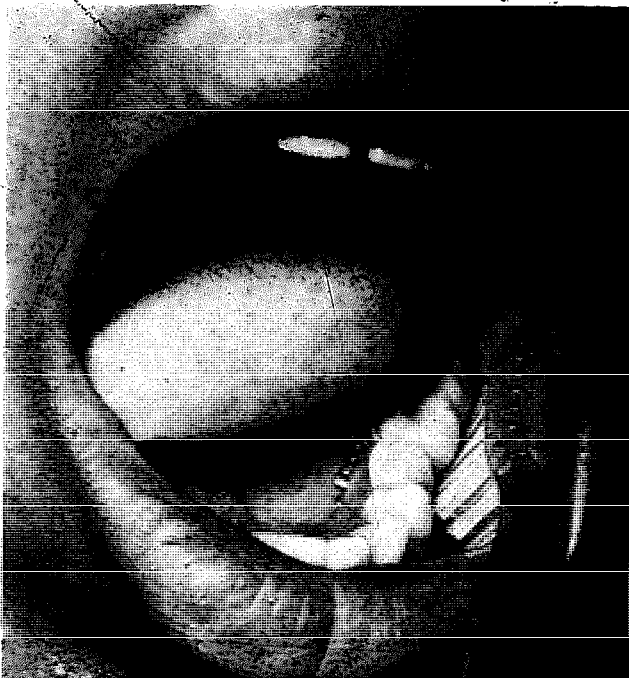FOODS THAT ARE GOOD FOR THE TEETH

These are those vegetables and fruits which are firm and fibrous and which have to be chewed hard: pineapple, mango, coconut, apple, raw cassava. It is a good idea to eat foods like this at the end of each meal.

HOW TO BRUSH THE TEETH AND GUMS



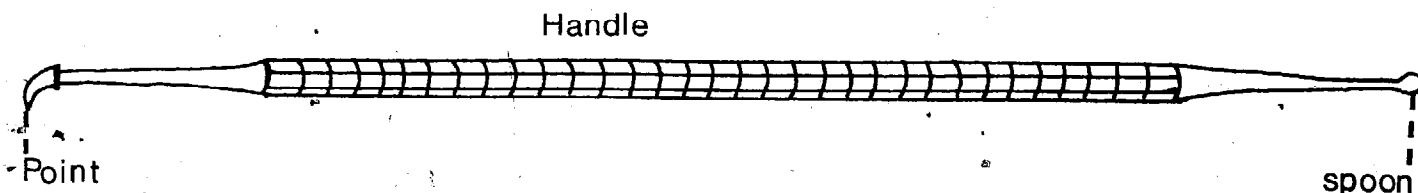
**Using a stick – shown here on the upper teeth:
start with the stick on the gums as shown above and brush downwards over the teeth**



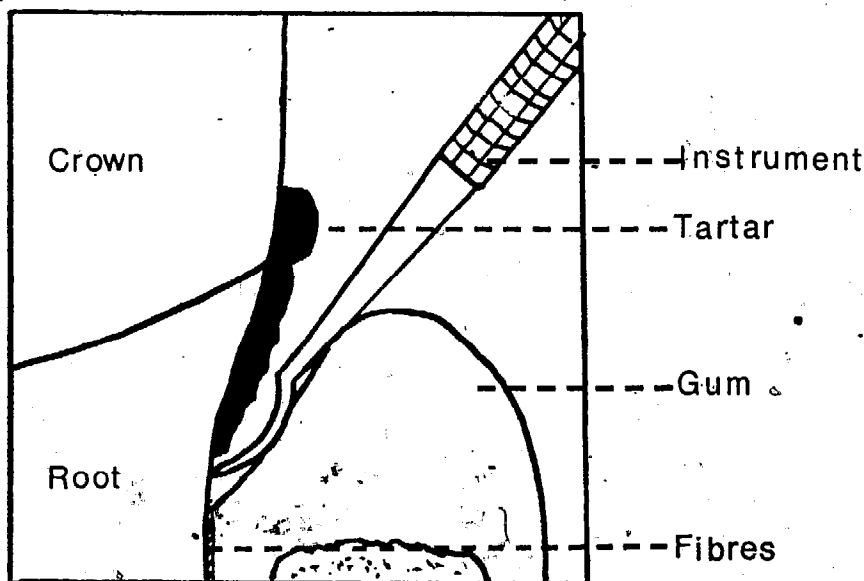
TREATMENT

SCALING THE TEETH

It has already been mentioned that many of the patients who complain of sore and bleeding gums have tartar round the teeth. To relieve the symptoms, this should be removed (Scaling), using the instrument shown below.



It is most important to *remove the deep tartar* which starts just below the gum. This is best done using the 'spoon' end of the instrument, but it is not always easy because the tartar sticks firmly to the teeth, and to remove it completely often causes mild pain and some bleeding.



The point of the instrument will help to remove the tartar between the teeth. After scaling, the patient should rinse the mouth thoroughly and be shown how to clean the teeth correctly.

If the gum disease is so advanced that the tooth or teeth are loose, it is not worthwhile scaling, and the only successful treatment is extraction.

EXTRACTING TEETH

INJECTIONS

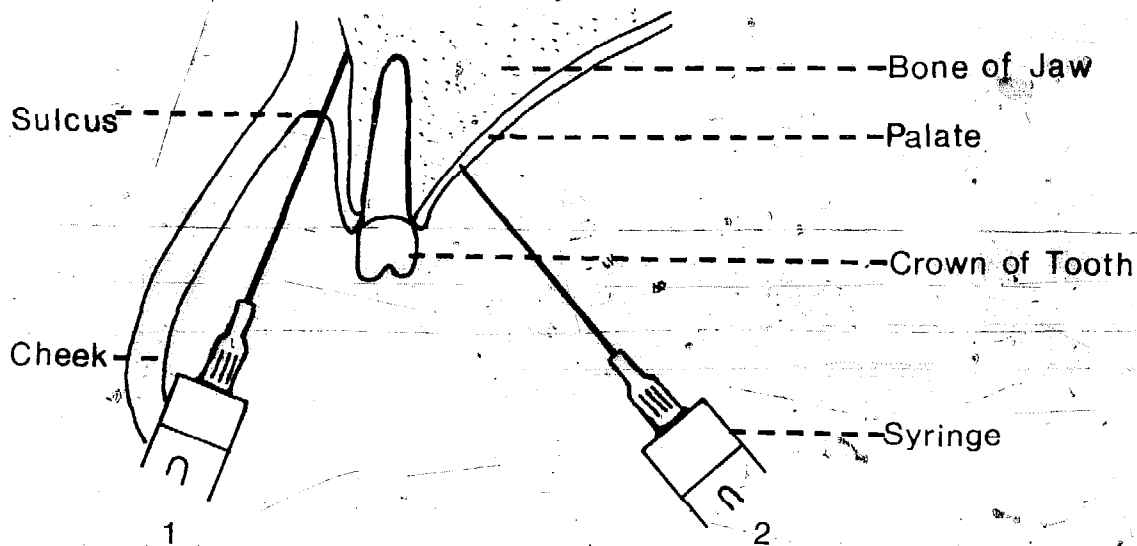
The pain of extraction can be prevented if a local anaesthetic is given properly. Before giving the injection:

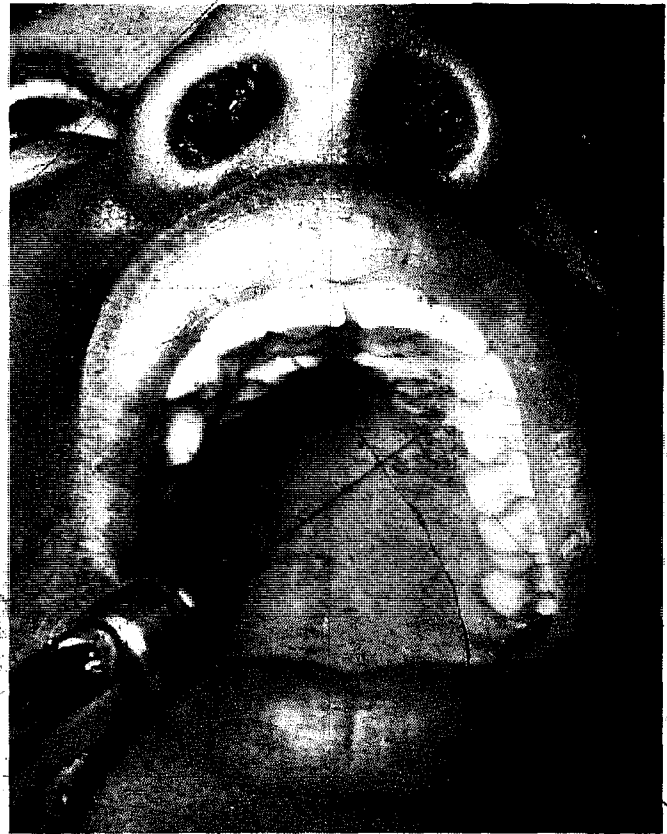
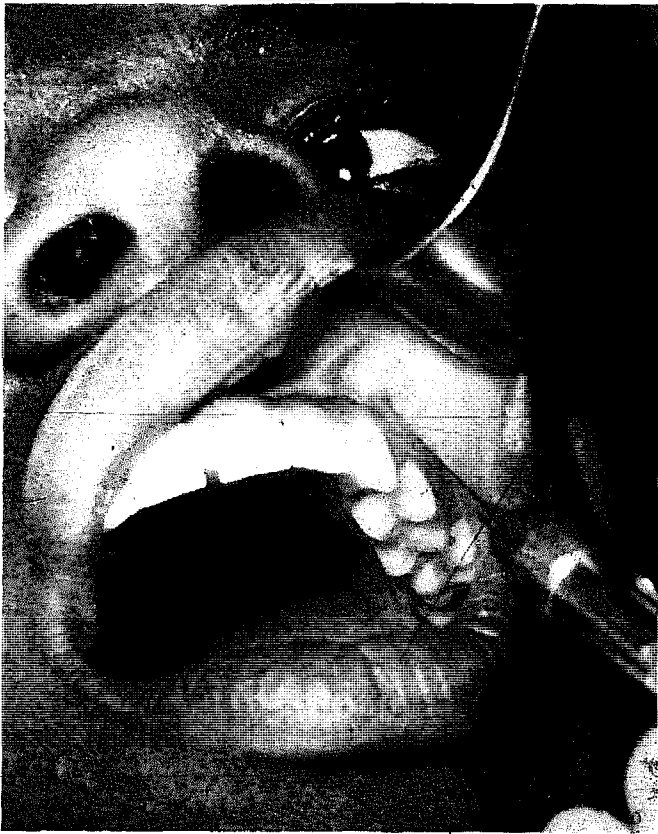1. Make sure you know exactly which tooth is painful and needs to be removed. Do not simply pull out the tooth which the patient points to, unless it can be seen that this has a big hole in it or is surrounded by severe gum disease. Sometimes the decay will not be easy to see if it is between the teeth. A mouth mirror may be helpful to look for such holes.
2. Ensure that there is no swelling. If there is an abscess present it should be treated with antibiotics, and when the swelling has disappeared the patient may have the tooth extracted. *It is dangerous to put a needle into a swelling* because this may spread the infection.

THE INFILTRATION METHOD

For the upper teeth

For each upper tooth two injections are needed, one on the inside and one on the outside. Both of these are infiltration injections.





For the outside injection

Hold the cheek back with one hand so you can see clearly the trough, or "*sulcus*", where the gum joins the cheek. It is here that the needle is pushed in, aiming so that its point comes to lie at the same level as the top of the root of the tooth to be extracted. It is helpful to think how long the root of the particular tooth is likely to be, so that the place of insertion, depth of insertion and angle of the needle can be estimated.

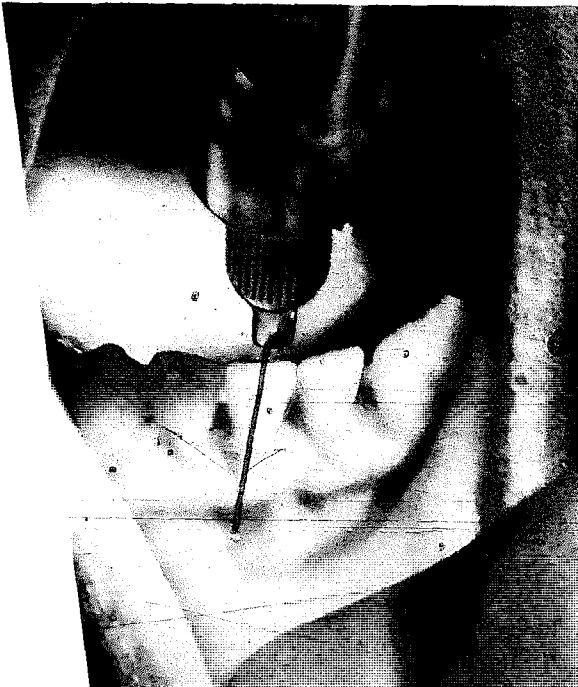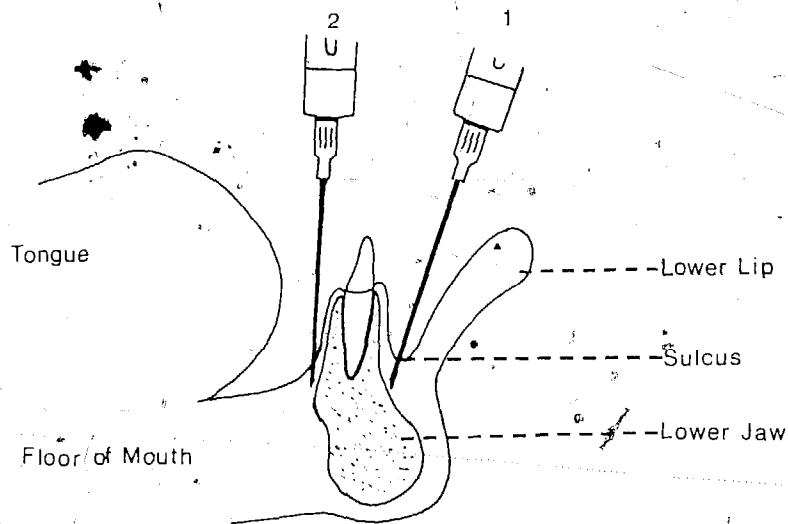
For front teeth it is possible to insert the needle in line with (parallel to) the tooth, but for molars near the back of the mouth this is impossible, so for an injection for a third molar tooth it is usual to insert the needle next to the second molar at such an angle that its point will come to lie next to the roots of the third molar. Inject just over half the cartridge, i.e. 1 cc (see page 25 "*Cartridge Syringe*").

For the inside injection

This is only a shallow one because the hard palate lies just below the mucous membrane of the palate. The needle is inserted opposite and one centimetre away from the tooth. The injection is a little painful and it is not possible to put much of the solution into the gum. Enough to make the gum go white is sufficient, but even for this amount it is necessary to press the syringe handle hard.

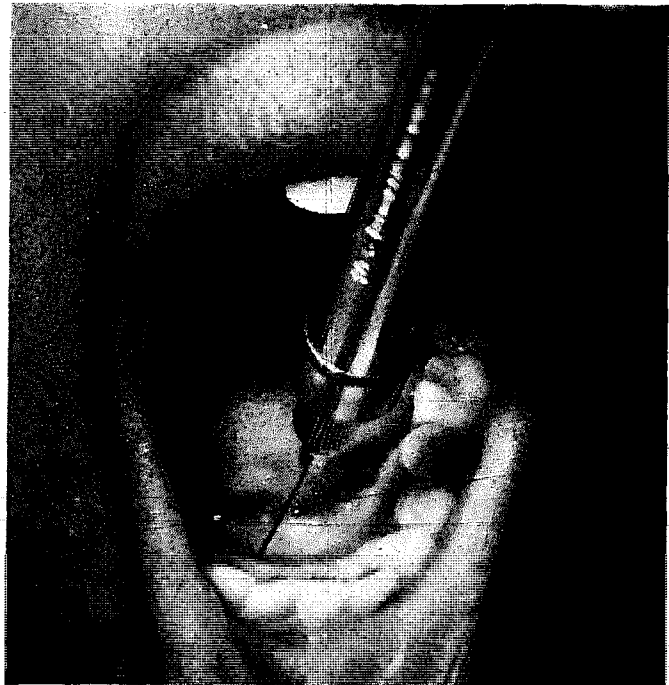
Injection for lower front teeth (canines and incisors)

The principle is the same as for the upper teeth.



The outside injection

Lower lip back so the sulcus is clearly seen. Push the point of the needle into the sulcus next to the tooth, to a depth of about a centimetre: the point of the needle is against the outside of the jawbone, and at the same time the needle is moved. Inject about half

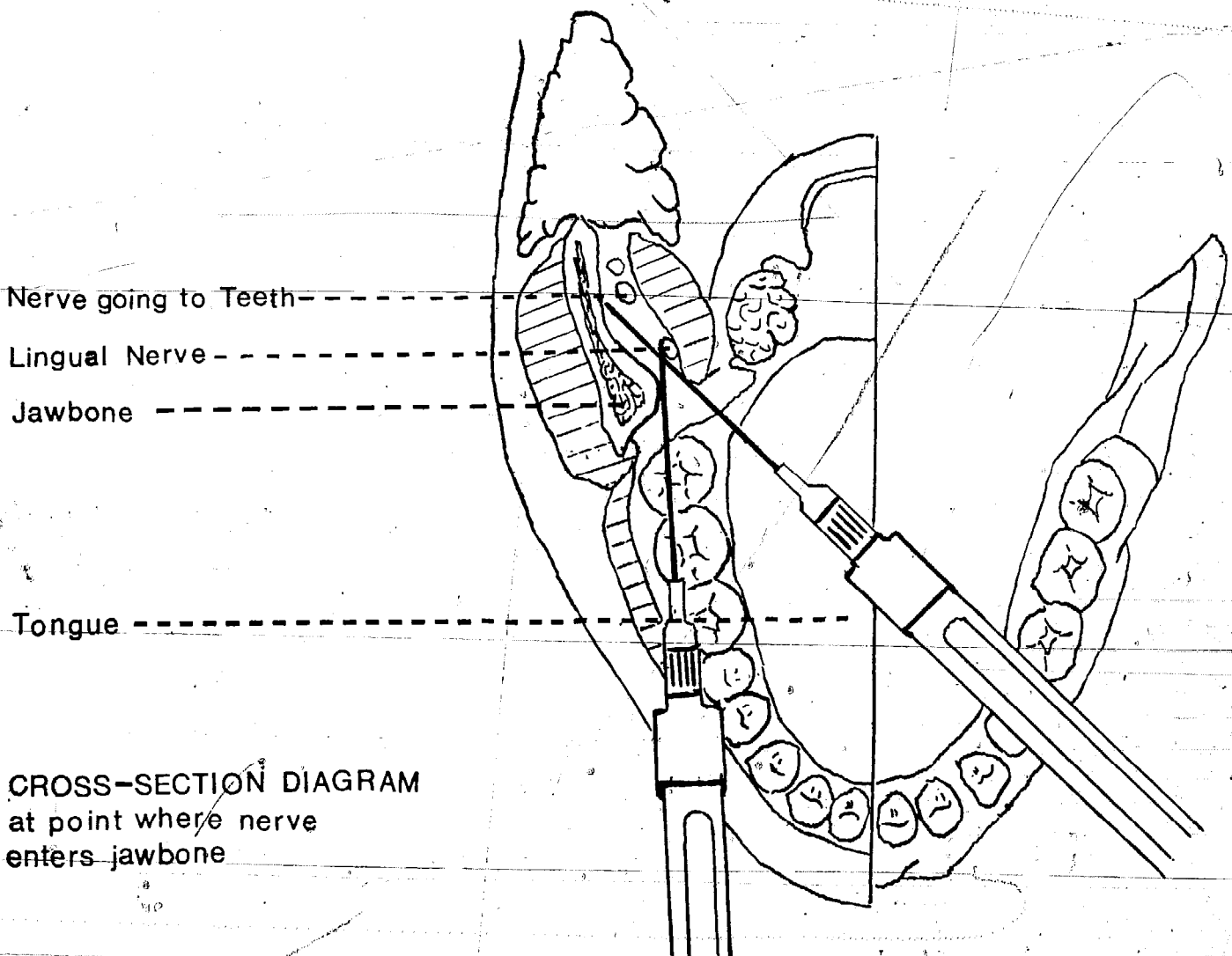
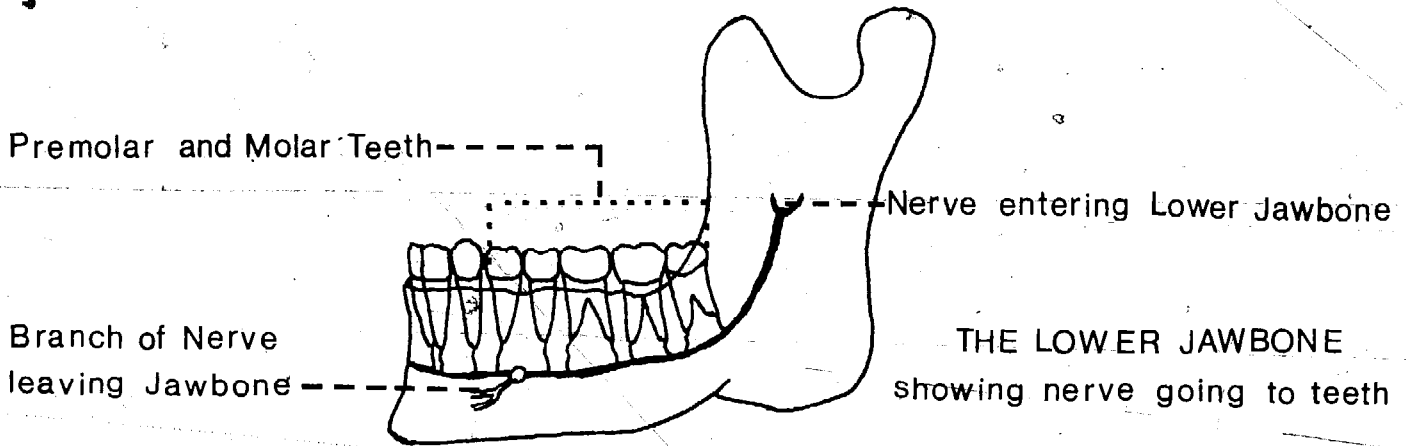


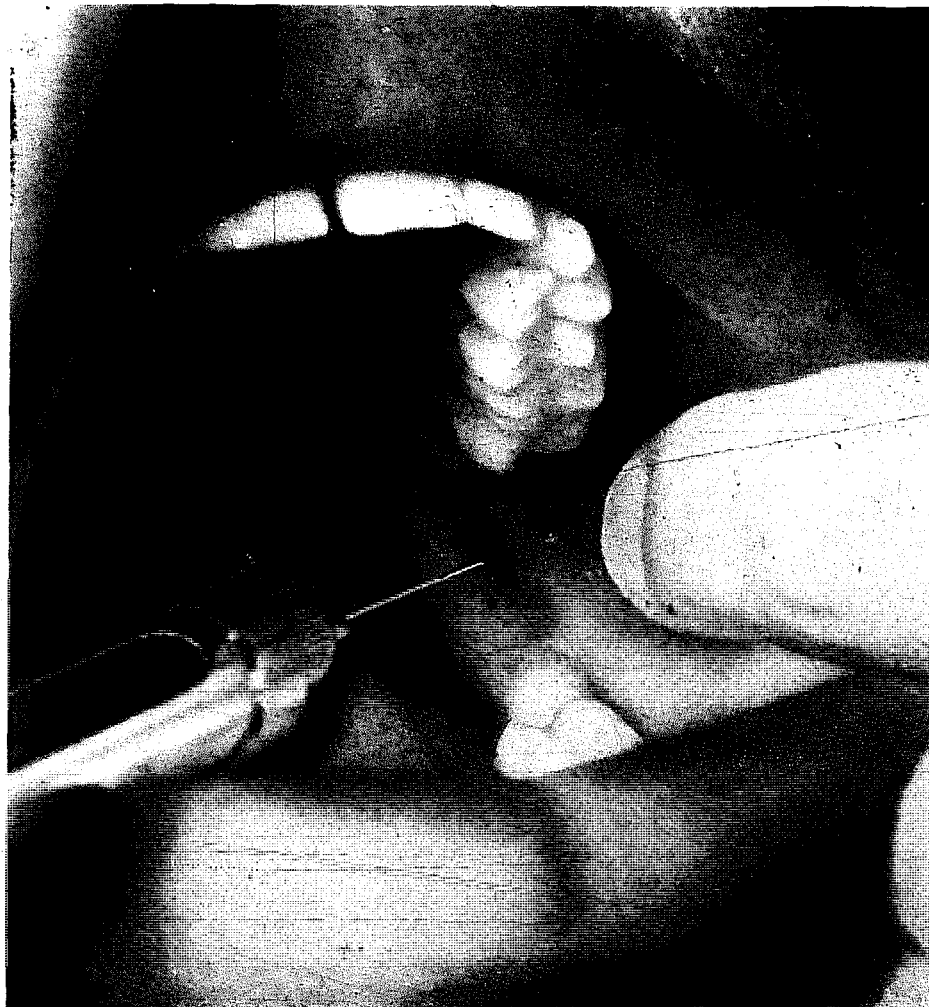
The inside injection

This is done in the same way. It may be necessary to hold the tongue out of the way to see the floor of the mouth. The needle is usually inserted into the floor of the mouth next to the inside of the lower jawbone only for a short distance. A small swelling will occur when the injection is given but this will go away quickly. Inject about a quarter of a cartridge.

THE NERVE BLOCK INJECTION FOR LOWER MOLARS

For the infiltration injections the solution passes from the needle through the bone to the nerve going into the tooth. These injections, however, are not very satisfactory for all lower molar teeth, and premolar teeth in some cases. If you wish to extract these teeth painlessly it is necessary to block the nerve which goes to them, as well as the nerve supply to the inside and outside gum.





The above picture shows what you see when the patient opens his mouth widely. A fibrous band (Pterygomandibular Raphe), which is normally prominent, connects the upper and lower jaws behind the teeth. Just lateral (outside) to this there is a depression lateral to which can be felt the anterior border of the lower jaw.

To give the injection

1. Ask the patient to open his mouth as widely as possible
2. Place the first finger of the left hand, as shown, at the angle of the lower jaw and feel for the deepest point of depression of the bone. (This is called the Coronoid Notch)
3. Place the point of the needle at the same level as the centre of your finger nail and just outside the fibrous band
4. Check that the angle of the needle is correct. The syringe should be resting between the premolar teeth of the opposite side of the mouth

5. Push the needle into the tissues until it comes against the bone of the lower jaw, which means it should be very close to the nerve you wish to anaesthetise
6. Withdraw the needle a very little and inject over half the cartridge of anaesthetic slowly
7. Withdraw the needle and when it is nearly out of the tissues turn it round so that it lies along the molar and premolar teeth of the same side. Inject one quarter of the cartridge and withdraw the needle completely. This is to anaesthetise the *lingual nerve*.

A second injection is necessary to anaesthetise the outside gum. This may be done in one of two ways.

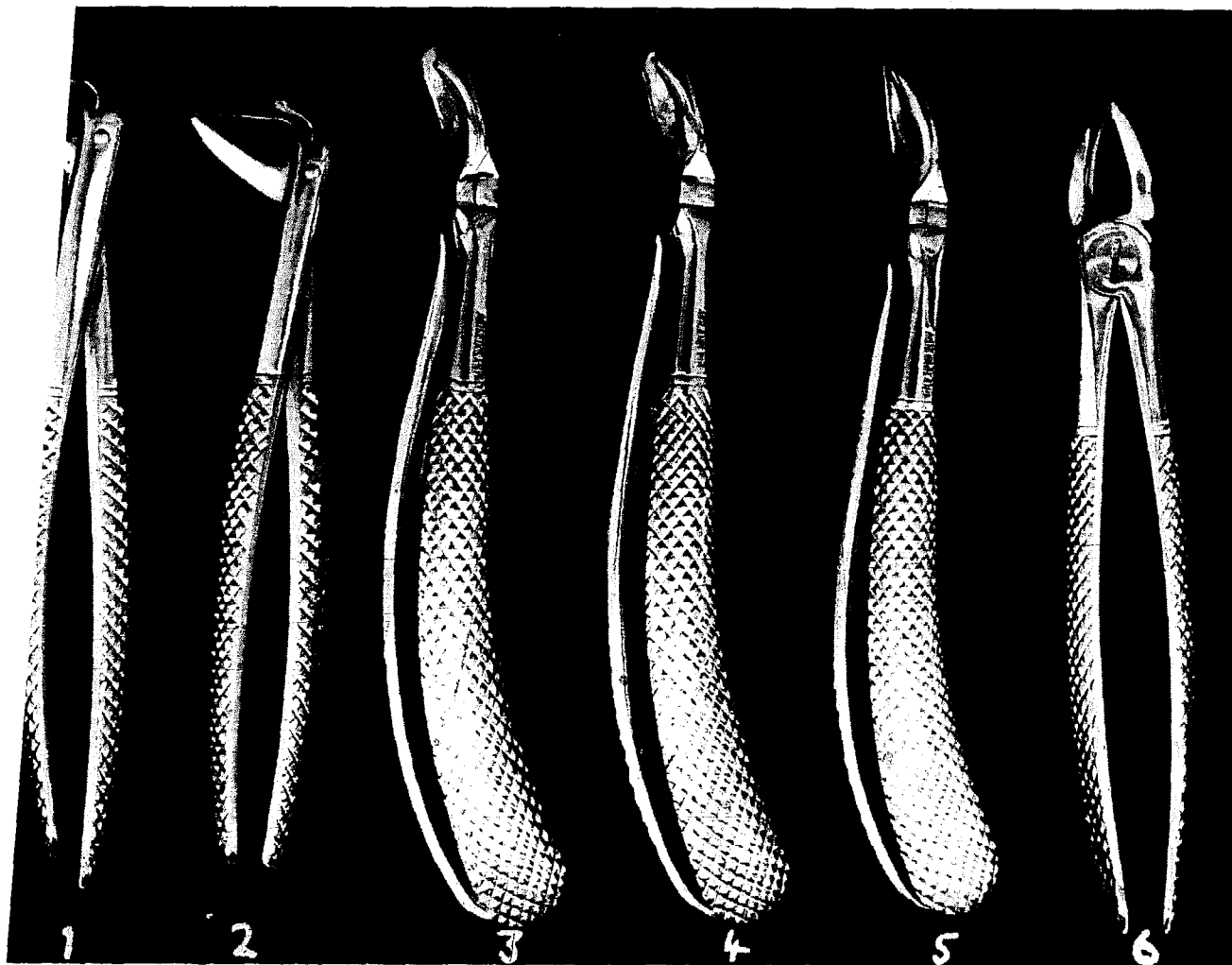
1. The infiltration method, as already described, may be used, one injection in the sulcus being needed for each tooth
2. One injection (block of Long Buccal Nerve) may be used to anaesthetise the outside gum of *all the lower molars*. To do this inject at the point where your finger was placed for the first injection. This is a shallow one because the bone of the lower jaw lies just under the mucous membrane at this point. This injection is at the same level as the first one but about a centimetre laterally towards the cheek.

TESTING FOR EFFECTIVE ANAESTHESIA

Before starting to remove the tooth wait for five or ten minutes to allow the anaesthetic time to work, then test it by pressing one beak of the forceps hard against the gum on both sides. If no pain is felt the anaesthetic is probably working. If pain is felt give a further injection on the side where it hurts, and wait another five minutes. For the nerve block injection the whole of one side of the face will feel 'heavy' and the lower lip will feel 'dead' on one side. When the tooth is successfully anaesthetised extraction may be carried out.

NOTE. It is advisable not to try the nerve block injection unless you have seen it demonstrated and done some under supervision, and it should only be carried out in places where there is a doctor so that he can be consulted if you have any difficulty when giving it. *Never push the needle completely into the tissues so that it is all buried* because if it does break (extremely unlikely) it can then be removed with a pair of Artery Forceps. *This should be done without delay*, before allowing the patient to close his mouth.

OF EXTRACTING TEETH



asic set of forceps, as shown above, consists of:

1. Lower Molar forceps
2. Lower Root forceps (for lower premolars, incisors, canines and roots)
3. Upper Left Molar forceps
4. Upper Right Molar forceps
5. Upper Premolar forceps (for upper premolars and roots)
6. Upper Straight forceps (for upper canines and incisors).

Extracting a tooth is always much easier if the correct forceps are used.

Skill at extracting teeth comes largely with practice. However, the following notes provide a guide for the inexperienced. It may be helpful to look at the picture on Page 3 where all the teeth are named.

Upper Incisors and Canines

These have a conical root form and a rotating movement combined with considerable force upwards will loosen them and then they may be removed easily.

Upper Premolars

These teeth have delicate roots so a slight side to side and rotating movement is required, together with considerable upward force. When the tooth is loose it may be pulled downwards out of the socket.

Upper Molars

Each of these teeth normally has three roots. The correct upper molar forceps should be selected (i.e. right or left). The pointed beak is to grip the outer side of the crown, the point itself sliding down between the two outside roots. Considerable upward pressure is again necessary while slight side to side movements are started to loosen the tooth. The movement is then increased, exerting more pressure in an outward direction, continuing until the tooth can be drawn out of the socket towards the cheek.

Lower Teeth

These have one or two oval shaped roots. Slight rotating movement, combined with a sideways movement between tongue and cheek is required. Constant downward pressure is necessary and it will be easier to apply this if the patient is sitting in a low chair. When the tooth is loose it may be pulled out towards the patient's cheek.

Position of Operator

For a right-handed person all the teeth except for the lower right ones can be removed by standing in front of the patient. The lower right teeth are extracted by standing behind.

Position of Patient

For lower teeth they should be sitting on a low chair so that downward pressure can be applied. For upper teeth a high chair is better so that the operator can push upwards easily. It is helpful for someone to support the patient's head against the upward pressure.

When extracting any tooth

1. Slide the forceps as deeply as possible along the root of the tooth.
2. Always push hard on the forceps towards the jawbone. (Upwards for upper teeth, downwards for lower teeth), when loosening teeth. If you do not do this you are more likely to break the roots.
3. Support the lower jaw with the left hand when extracting any lower teeth.
4. For upper teeth, place the finger and thumb of the left hand on the gum either side of the tooth to be extracted while loosening it.

After the Extraction

The patient may rinse the mouth out to wash away blood, but after this one rinse no more rinsing should be allowed until the following morning. Further rinsing will wash away blood in the socket forming the blood clot which is essential for quick painless healing. The patient may eat and drink whenever he wishes, but should do this on the other side of the mouth. The following morning rinsing with warm salt water should be started. (Cup of water with one small spoonful of salt.) This will keep the socket clean and help the healing. This should be repeated after meals for the next five days.

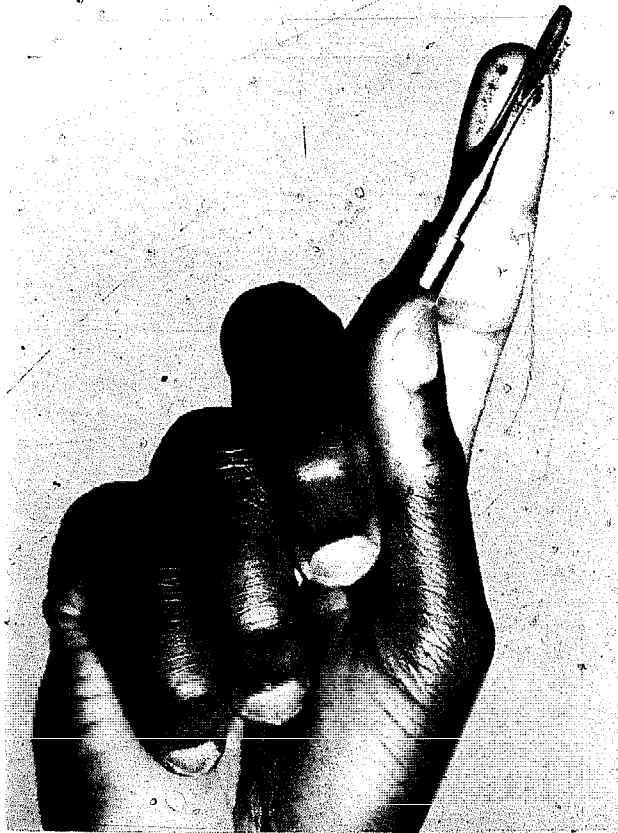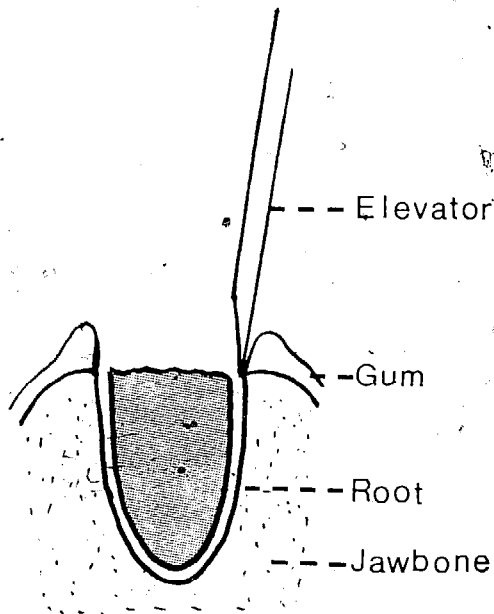
BROKEN ROOTS

Occasionally roots will be broken during extraction. If only the bottom third is left it is better to leave it alone as healing will usually take place normally.

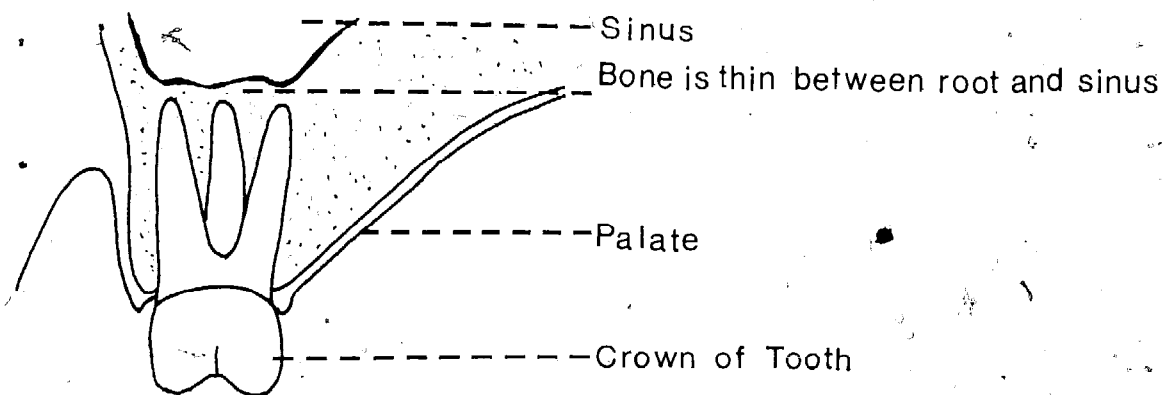
If a large piece of root is present an attempt may be made to remove it with the *inclined plane elevator*.

Place the elevator between the root and the socket as shown, and while pressing firmly rotate a little each way, attempting to drive the instrument towards the bottom of the socket. It should act like a wedge and move the root out of the socket. This method may also be used for loosening very firm teeth.

Always hold the elevator with the first finger near the end of the blade, as shown, so that should the instrument slip it will not travel far and cause unnecessary damage to the gums.



For upper premolar and molar roots *very little upward pressure* should be applied, and if the root does not come easily it is better to leave it alone. If it begins to move towards the *sinus* stop immediately and inform the doctor because if the root passes into the sinus this may become infected and special treatment may then be needed. If you are in any doubt, do not use the elevator on upper premolars and molars.



Do not spend long trying to remove roots. If they do not come easily leave them alone and ask the patient to return in a week's time when they may have loosened and it will be easier to take them out. While the root is still present, tell the patient to be very careful about keeping the mouth clean, using warm salt water rinses, and to return to hospital earlier if there are any signs of infection. (Severe pain or swelling.) Give the patient a few aspirin tablets as there will probably be some pain.

COMPLICATIONS AFTER EXTRACTION

BLEEDING AFTER EXTRACTION

If there is much bleeding immediately afterwards, place a pad of damp gauze or cotton wool over the socket and ask the patient to bite on it for half an hour. The pressure normally stops the bleeding.

If a patient returns later that day with further bleeding, try the above method again, but if it fails ask the doctor to see the patient, and he may decide to place a few tight sutures across the socket. This usually deals with even the most persistent 'bleeders'.

Another method is again to ask the patient to bite on a damp pad of gauze placed over the socket and then to apply a bandage for several hours (usually overnight) to keep the mouth firmly closed. The bandage, which is made from a long narrow length of strong cloth, is passed beneath the chin and round each side of the face to be tied tightly on top of the head.

A BROKEN ROOT WHICH CANNOT BE REMOVED

If this is causing much pain or infection refer the patient to the doctor, who may then decide to send him to a dental surgeon.

SWELLING AFTER EXTRACTION

This is due to infection in the tissues round the teeth, and may arise from a piece of tooth which has been left in, directly from the mouth, or from an unsterile needle. It is most important that needles should be thoroughly sterilised in boiling water for twenty minutes before use.

Treatment

Rinse out the socket with Hydrogen Peroxide and then refer the patient to the doctor, who may then decide to prescribe an antibiotic.

DRY SOCKET

This is a very painful condition which is first noticed a few days after the extraction. There is no blood clot in the socket and often it is filled up with food.

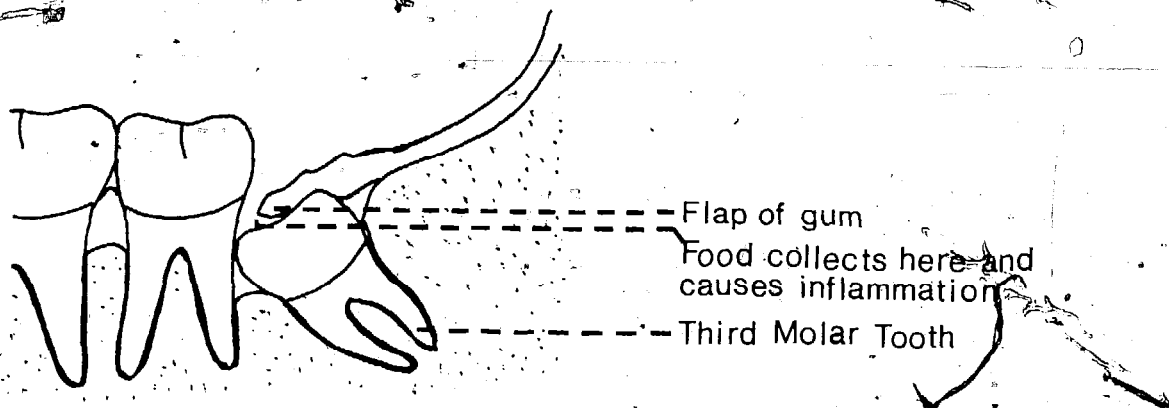
Treatment

Wash the socket out by using a syringe with a weak solution of Hydrogen Peroxide. This will clean out the food. Place in the socket a small piece of cotton wool soaked in a strong antiseptic. One containing iodoform is very effective. Tell the patient to keep the mouth clean by rinsing with warm salt water. After three days he should come again for removal of the cotton wool and further syringing with Hydrogen Peroxide. If there is still a big hole present another plug of cotton wool should be placed there. A third visit by the patient may be necessary in bad cases. Aspirin tablets should be given as this is a painful condition.

OTHER DENTAL DISEASES

PERICORONITIS

This means inflammation of the gum round a tooth and is most often seen next to the last molars, especially the lower ones. It may only last a short time during the eruption of these teeth, but it may persist if they are unable to come through the gum completely when there is not enough room for them in the mouth.



Treatment

1. Clean the area round the tooth using a syringe with warm antiseptic (e.g. Hydrogen Peroxide)
2. Tell the patient to keep his mouth clean by using warm salt water mouth rinses, four times a day, after meals.

If the condition does not improve after carrying out this treatment a few times, or there is much swelling, consult the doctor. The patient may be advised to visit a dental surgeon for the removal of the last molar because sometimes this is the only way of permanently curing the inflammation.

TEETHING

The time when the teeth begin to come through the gums of a baby is known as "teething". This is sometimes painful and the baby is unhappy. The best way to help such a child is to advise the mother to keep his mouth clean by washing the food away from around the erupting teeth, using a piece of wet cotton wool or small damp rag. At this time in the child's life there is often diarrhoea and vomiting which some people believe is caused by the teeth coming through. The unkind practice of cutting the gums in an effort to stop the diarrhoea, which is still occasionally carried out in a few regions, does not help at all and often leaves the child with a very sore infected mouth. Every effort should be made to encourage mothers not to continue this harmful custom.

CONCLUSION

What has been written in this booklet is meant as a reminder of what you have already been taught. It is good to tell others about the diseases of the teeth and gums and the ways of preventing them, but no attempt should be made to tell others about the methods of injection and extraction. This teaching should only be carried out by a qualified person.

Remember, you are working under the doctor and if you are not certain how to treat a patient ask his advice. Do not attempt any treatment about which you have not learnt and which is not in this book.

IF IN DOUBT ASK THE DOCTOR

PREVENTION IS BETTER THAN CURE. It is not necessary to wait until patients come complaining of sore gums and bad teeth to instruct them how to brush their teeth correctly. This advice can be given to anyone, especially patients in the wards and children in hospital or at school.

Dental education and the encouragement of preventive measures is the most effective way to deal with the increasing problem of dental disease. If this is to start anywhere it must surely start in your country's hospitals, which means it is up to you who work there to teach people how to look after their teeth and gums.


PRACTICAL NOTES

DENTAL INSTRUMENTS

Dental Forceps: The six patterns described in this booklet are considered the basic minimum for routine work in Africa where, owing to a dense bone structure and well developed roots, the teeth sometimes require more effort for their removal than their counterparts in Europe. The great stress placed on the forceps falls heavily upon the joints so when purchasing them it is important to ensure that they are well made and have a "precision" joint, if this is not to become loose after a while.

These forceps may be obtained from the Amalgamated Dental Company of Britain, 26/40 Broadwich Street, London, W1A 2AD. Catalogue numbers 73, 74, 18, 17, 7 and 2 (numbers in the same order as list on page 18).

Cartridge Syringe: This is the most convenient pattern for dental use and was provided at many of the hospitals visited by the author because the 2 cc cartridges of anaesthetic solution could readily be obtained in Uganda. The most suitable type is Lignocaine, 2% with a small fraction of adrenalin added. Good proprietary brands include Lidesthesin, Lignostab A, Xylotox E.80. These syringes take fine needles: 26 gauge, 1 1/2" is recommended. Although thin, modern makes are by no means brittle and the risk of breakage in use is extremely unlikely.



Other types of Syringe: Although the above pattern is the ideal, any small syringe used in conjunction with a fine needle and suitable anaesthetic solution may be employed. If Lignocaine is not available, Procaine may safely be used. However, in either case better results will be obtained if the solution is one which contains adrenalin.

Scaling Instruments: An excellent pattern is *Cumine 152*, which can be obtained from the Amalgamated Dental Company of Britain. It is most important that this instrument is kept sharp if it is to be used efficiently.

A DENTAL CHAIR

It was found that very few hospitals possessed dental chairs, so a headrest was devised to adapt a sturdy upright chair to support the head. Several enquiries were made about how this unit could be made, so consequently it has been decided to include the following explanatory diagrams in this edition, which it is hoped can be understood by the hospital carpenter.

