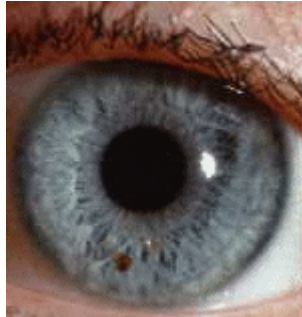

Study of Eyes Iridology

Iridology



Iridology, also known as iridodiagnosis, is an alternative medicine practice in which patterns, colors, and other characteristics of the iris are examined for information about a patient's systemic health. Practitioners match their observations to iris charts which divide the iris into many zones believed to correspond to specific parts of the human body. Little, if any, rigorous scientific evidence exists confirming any such link between aspects of the iris and a patient's state of health and there is no recognized causative mechanism for any purported correlation.

Iridologists claim that they do not diagnose specific diseases, but rather that they "highlight" those systems and organs in the body that are healthy and those which are described as "overactive" or "inflamed." These are said to point to a tendency in the patient towards certain illnesses, to reflect past medical problems, or to predict health problems which may be developing.

Since iridology is not a method of treatment, its practitioners have often studied other branches of alternative medicine, such as naturopathy, and used the study of the iris as a diagnostic first step. Iridology is practiced more widely in Europe (especially in the UK and Germany), where there are approximately 20,000 practitioners, than in the United States, which has only a tenth of that number.

Methods

Iridologists generally use equipment such as a flashlight and magnifying glass, cameras or slit-lamp microscopes to examine a patient's irises for tissue changes, as well as features such as specific pigment patterns and "irregular stromal architecture". The markings and patterns are usually compared to an iris chart that correlates specific zones of the iris with specific parts of the body. Typical charts divide the iris into approximately 80-90 zones. For example, the zone corresponding to the kidney is often in the lower part of the iris just before 6 o'clock. However, iridologists use a number of different maps that do not necessarily agree with one another.

According to iridologists, details in the iris are supposed to reflect changes in the tissues of the corresponding body organs. For example, acute inflammatory, chronic inflammatory and catharral signs are said to indicate involvement, maintenance, or healing of corresponding distant tissues, respectively. Other features that iridologists look

for are contraction rings and Klumpenzellen, which are said to indicate various other health conditions, as interpreted in context.

History

Examining a person's eyes to help determine their health is an ancient practice dating back at least as far as the ancient Greeks.

The first explicit description of iridological principles such as homolaterality (without using the word iridology) are found in *Chiromatica Medica*, a famous work published in 1665 and reprinted in 1670 and 1691 by Philippus Meyeus (Philip Meyen von Coburg).

The first use of the word Augendiagnostik ("eye diagnosis," loosely translated as iridology) began with Ignatz von Péczy, a 19th-century Hungarian physician. The most common story is that he got the idea for this diagnostic tool after seeing similar streaks in the eyes of a man he was treating for a broken leg and the eyes of an owl whose leg von Péczy had broken many years before. At the First International Iridological Congress of Iridology, Ignaz von Péczy's nephew, Dr August von Péczy, dismissed this myth as an apocryphal, and maintained that such claims were irreproducible.

German contribution in the *Naturheilkunde* field is due to a minister Pastor Felke, who developed a form of homeopathy for treating specific illnesses and described new iris signs in the early 1900s. However, Pastor Felke was subject to long and bitter litigation. The Pastor Felke Institute in Heimshiem, Germany was established as a leading center of iridologic research and training.

Iridology became popular in the United States in the 1950s, when [Bernard Jensen](#), an American chiropractor, began giving classes in his own method. This is in direct relationship with P. Johannes Thiel, Eduard Lahn (becoming an American under the name of Edward Lane) and J Haskell Kritzer. Jensen insisted on the body's exposure to toxins, and the use of natural foods as detoxifiers.

Few medical researchers managed to secure funding to study the possible non-visual functions of the eye. In a paper published in *Medical Hypotheses*, one such group tried to explain the observed patterns of iris transparency that distribute light into the *ora serrata* (the edge of the optic retina) by postulating a so-called *functio ocularis systemica*. Based on this hypothesis, the researchers have developed the experimental trans-iridal light therapy method; however, no independent confirmation of the theory and method exists to date. Other results from the mentioned research include early attempts at computerized iris imaging for the purpose of iridologic diagnosis.

Support for Iridology

Practitioners of iridology point to the following benefits of iridology:

1. Their examination is non-invasive. The only thing patients have to tolerate is light being shone in the eyes.
2. Iridologists aim to keep the patient well. They try to discover imbalances or weaknesses in the body before they develop into serious medical problems. Of course prevention of health problems is a central concept of all schools of

medicine. Iridologists' advice on how to keep the patient well is frequently good. For example, they may recommend a good diet, drinking plenty of water, and moderate exercise.

Scientific Research into Iridology

Scientific research into iridology has shown mostly, but not entirely, negative results. However, all double blinded, rigorous tests of iridology have failed to find any statistical significance to iridology.

In a study published in the *Journal of the American Medical Association*, three iridologists incorrectly identified kidney disease in photographs of irises and often disagreed with each other. The researchers concluded: "iridology was neither selective nor specific, and the likelihood of correct detection was statistically no better than chance." Iridologists defended themselves by stating that they needed live examinations and that their approach was valid for predictions of health, not of disease tags once the disease was developed and even complicated. However the three iridologists concerned did not state that before the study took place.

Another study was published in the *British Medical Journal* (Knipschild⁴, 1988). Paul Knipschild MD, of the University of Limburg in Maastricht, selected 39 patients who were due to have their gall bladder removed the following day, because of suspected gallstones. He also selected a group of people who did not have diseased gall bladders to act as a control. A group of 5 iridologists examined a series of slides of both groups irises. The iridologists were not able to identify correctly which patients had gall bladder problems and which had healthy gall bladders. For example one of iridologists diagnosed 49% of the patients with gall stones as having them and 51% as not having them. He diagnosed 51% of the control group as having gall bladder problems and 49% as not. Dr Knipschild concluded: "this study showed that iridology is not a useful diagnostic aid." Iridologists defended themselves with the same considerations as above, but also attacked the methodology of the study.

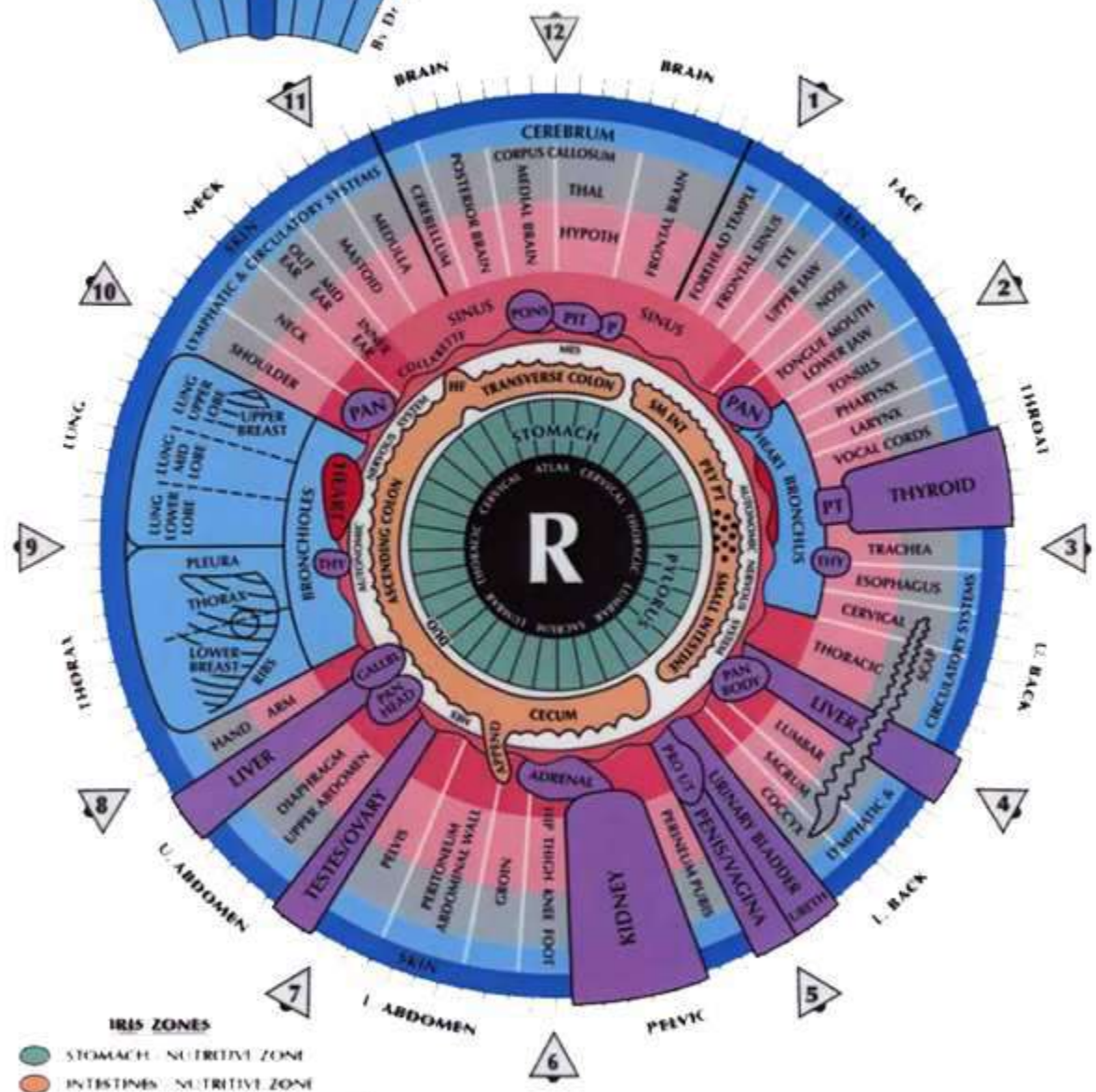
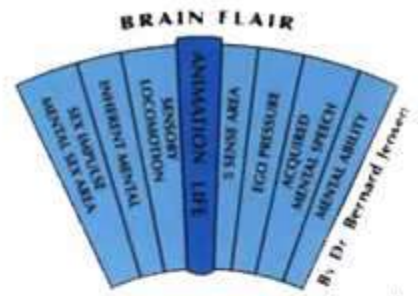Ernst⁵, 2000, said: "Does iridology work? This search strategy resulted in 77 publications on the subject of iridology. All of the uncontrolled studies and several of the unmasked experiments suggested that iridology was a valid diagnostic tool. Such investigations are wide open to bias. The discussion that follows refers to the 4 controlled, masked evaluations of the diagnostic validity of iridology. In conclusion, few controlled studies with masked evaluation of diagnostic validity have been published. None have found any benefit from iridology. As iridology has the potential for causing personal and economic harm, patients and therapists should be discouraged from using it."

Demea⁶, 2002, showed a positive result for iridology: "The research proposal is to evaluate the association between certain irian signs and general pathology of studied patients. There were studied 57 hospitalized patients The correlations resulted from, shows a high connection between the irian constitution establish[ed] through iridological criteria and the existent pathology. Iris examination can be very useful for diagnosis of a certain general pathology, in a holistic approach of the patient." (translation as per abstract) However, the absence of the required formal criteria for reliable evidence in health care (blindedness, lack of bias,

<http://www.crystalinks.com/iridology.html>

Iridology Eye Chart of the Right Eye Dr. Bernard Jenson's Iridology Chart

IRIDOLOGY CHART



- IRIS ZONES**
- STOMACH - NUTRITIVE ZONE
 - INTESTINES - NUTRITIVE ZONE
 - BLOOD & LYMPH - HUMORAL ZONE
 - MUSCULATURE
 - BONY STRUCTURE
 - SUPERFICIAL LYMPH & BLOOD
 - SKIN & ORIFICES
- INTERNAL ZONES

- [Dr. Bernard Jenson's Iridology Eye Chart for the left eye ...](#)
- [Iridology Eye Pictures ...](#)
- [Learn more about about Iridology in Mississauga \(Toronto\) Canada ...](#)
- [Iridology Analysis by a Certified Iridologist ...](#)

To book your Iridology Analysis call (905) 855-3000

Iridology Chart of the Left Eye

Dr. Bernard Jenson's Iridology Eye Chart

- [Dr. Bernard Jenson's Iridology Eye Chart for the right eye ...](#)
- [Iridology Eye Pictures ...](#)
- [Learn more about about Iridology in Mississauga \(Toronto\) Canada ...](#)
- [Iridology Analysis by a Certified Iridologist ...](#)

To book your Iridology Analysis call (905) 855-3000

http://www.healthyyounaturally.com/services/iridology/left_iridology_eye_chart.htm

Notice Iris Markings and Compare Them to Iridology Charts

1. Step 1

Look for black markings. Black indicates dying tissue and is most common when the area indicated has scarring. Compare the markings seen on the iris to its location on the chart to learn where this scarring is likely to exist.

2. Step 2

Look for white markings, like small dots or lines. White indicates [inflammation](#). It may mean that a particular area of the body is becoming overwhelmed. Consult the iridology chart to see which organ or system is experiencing this inflammation.

3. Step 3

Look for rings and arcs around the iris. These may indicate a number of things. Smaller contraction rings may indicate spasms of a particular organ. A sodium ring at the edge of the iris may indicate slow [metabolism](#).

4. Step 4

Be aware of what sectors of the iris correspond to which areas of the body. Consult your chart. A basic chart is available at Irisdiagnosis.net (see Resources below).

5. Step 5

Commit the basics of the chart to memory. The brain section is represented at the top of the iris. The colon is further in, closer to the pupil. Problems with the lungs, heart and spleen are indicated on the right side of the iris.

Problems with the nose, larynx, thyroid and spine can be found on the left side.

6. Step 6

Learn more about iridology examinations, the history of the practice and how to read iridology charts at the "Iridology Now" Web site (see Resources below).

Tips & Warnings

- Only a certified iridology practitioner should diagnose problems using an iridology chart. Novices can certainly read and use a chart for fun. Classes and certification are available from the International Iridology Practitioners Association (see Resources below).
- A quality iridology chart is inexpensive. Iridology [cameras](#) can be pricey.
- Visiting an iridology practitioner should be inexpensive to moderately priced.
- If you experience acute chest pain or other serious symptoms, seek medical attention immediately.
- Before you start any alternative medical technique, be aware that many have not been scientifically evaluated. If you decide to try iridology, keep your doctor informed about the treatment you undertake.

http://www.ehow.com/how_2033050_read-iridology-charts.html

Iridology Glossary of Terms

Angle of Fuch's:

This is when the Collarette is extremely raised (looks like a mountain range) and it means that there is difficult assimilation, absorption and putrefaction.

Central Heterochromia:

Is pigment in nutritive zone or around the collarette. This indicates tendency to malabsorption and toxins in nutritive zone. Color varies according to which organs or tissue systems are involved.

Ciliary Zone:

This is the area of the iris outside the collarette to the iris edge. (Where you see the iris fibers).

Collarette:

In American Iridology is known as the ANW. It separates the nutritive zone from the rest of the ciliary body. If it is tight it shows stricture, contraction, irritability, and inflammation.

Undefined Collarette indicates spasms, colic, neurological disturbances and a delicate nervous system. Thick and raised collarette indicates gastrointestinal problems, food intolerance, lymphatic insufficiency and environmental sensitivity. Misshapen, thick, and indented collarette indicates stricture, deformation, and motor disturbances. Absences of collarette indicates spasms, appetite disorders and mineral absorption problems. If the collarette is jagged it shows irritation to the gastrointestinal system. PERSONALITY: Wide Collarette = outgoing, more sensitive, can get scattered easily. Tight Collarette = reserved, uses caution. Outside stress causes retreat, introverted.

Density:

Is measure of resistance (inherited strength). How well you resist negative influences. For example, a strong body will be able to resist all negative influences for a longer period of time.

Nutritive Zone:

This is the area between the pupil and the collarette (the gastrointestinal system).

Pinguecula:

Is a yellow fatty "blob" that arises from the sclera. In most cases, this indicates that the body is not handling fats properly.

Prolapsus of Transverse Colon:

This only means that there is connective tissue weakness in the colon. It does not mean that the transverse colon has dropped down or is sagging.

Psora:

Pigments that are gathering to protect organ reaction field underneath it and to keep light from coming in.

Pterygium:

This is a thick white growth appearing on the conjunctiva of the eye and is usually caused by trauma or constant irritation to the eye, such as blowing dust.

Pupil Size:

Shows the condition of the autonomic nervous system. Also, when you are looking at the pupil size, you are looking at the spine. Work with the Pupil Tonus Chart. Constriction of the pupil is caused by the sphincter pupillae, a muscle encircling the pupillary margin deep inside the stroma layer. The dilator layer, consists of a thin layer of plain muscle fiber. When it contracts, it draws the pupillary margin inward and this dilates the pupil.

Pupillary Margin or Pigment Ruff:

Is located around the pupil. Darkly pigmented layer, an extension of Posterior epithelium. If the Pupillary Margin appears to have "holes" in it, this means diabetes. The normal color is reddish brown. This is principally an analog for the spine.

Radials:

In American Iridology, these are Iris Fibers. In the ciliary zone these are blood vessels running radially. These are enmeshed in connective tissue. They run toward the pupillary zone, through the

ciliary zone of the iris. The vessels become wavy as the pupil dilates and straighten out as the pupil constricts. Also known as Trabeculae. (Trabecula = 1 & Trabeculae = 2)

Rarefaction:

Separation of fibers, but not lacuna or crypt.

Shading:

Reactivity (contrast between light and dark). Light = more reactivity, inflammation, elimination or pain. Dark = suppressed, body cannot react sufficiently. NOTE: When there is lightness next to darkness, this means the body is trying to fight, despite a chronic condition.

Tobacco Snuffing:

Dark "dots" gathered together in any area of the iris. Indicates tendency to weakness in liver, or can mean liver damage. Some call it "pepper corns."

Topo Labile:

Any marking in iris that indicates a weakness in specific organ but can be found anywhere in the iris. Significance is determined by its structure or color, not by its location in the iris map. For example, a brown pigment indicating liver weakness, even if it is located near the heart area.

Topo Stable:

Marking found in the iris in a specific area of the body which affects that related part of the body. In other words, a marking found in the heart area which specifically means a weakness in the heart.

Trabecula or Trabeculae:

See Radials

Transversal:

It travels across the iris "grain." If it is white, this means inflammation or pain. The body is reacting to an abnormal situation in the body. Significance can range from inflammation to sensitivity to latent cancer depending upon configuration and location.

Can also indicate displacement of organs.

Vascular Transversal:

Is a transversal that is missing the Schwann sheath or the Schwann sheath has been worn off (connective tissue). Is a more serious sign than the white transversal. Joseph Deck states that the Vascular Transversal indicates "inherited tendency to malignancy." Is pink or red in color. Can indicate serious tissue changes, high degree of congestion and sometimes pain. Always indicates some stage of venous stagnation.